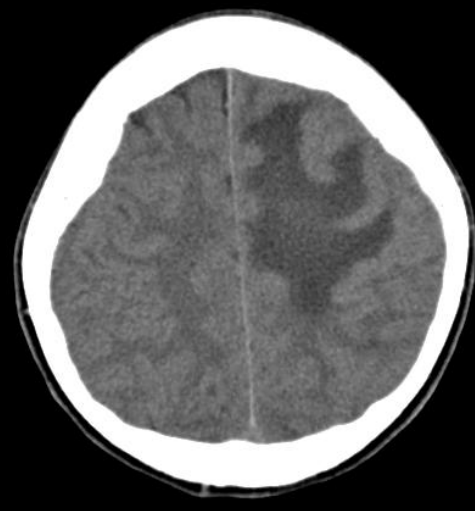
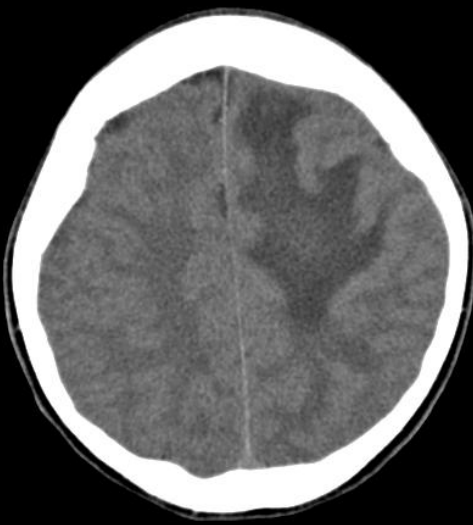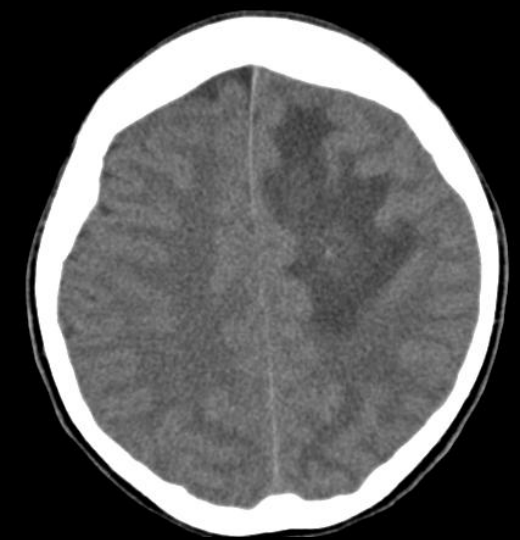
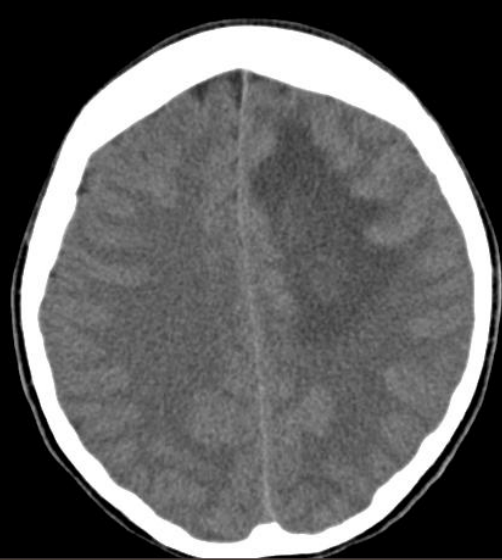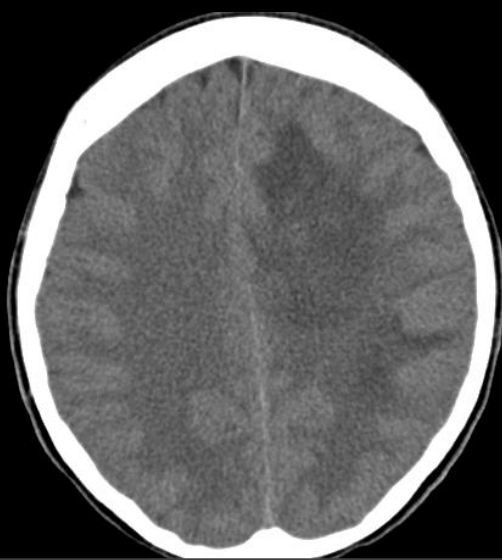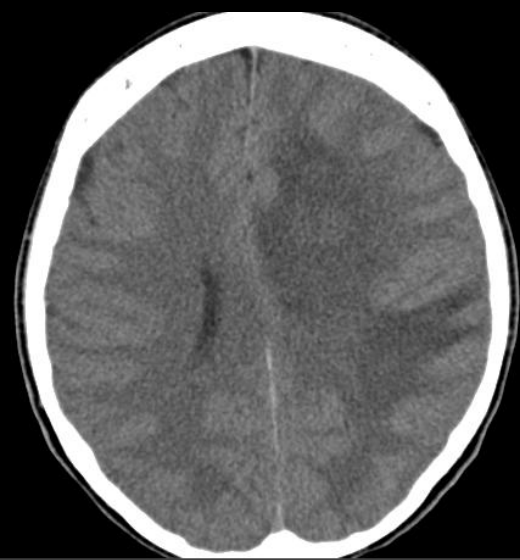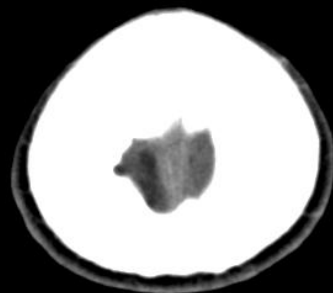
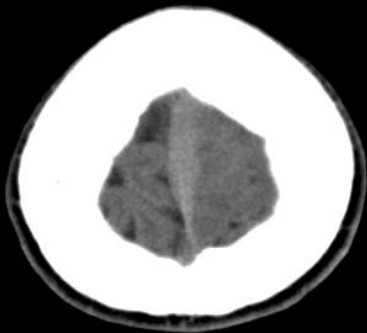
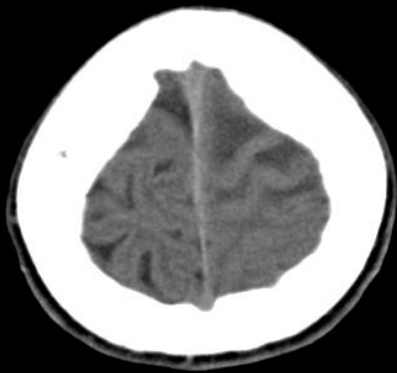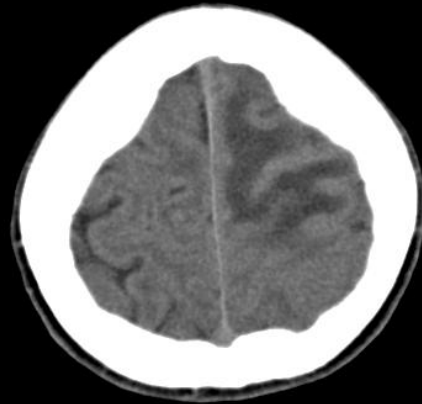
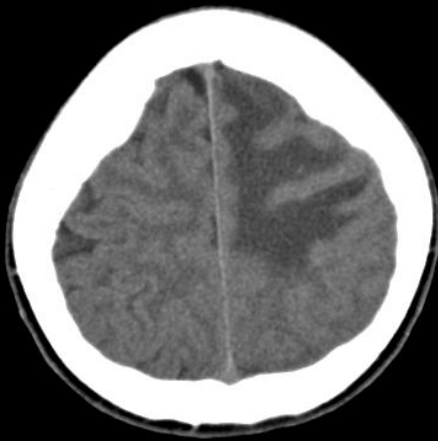


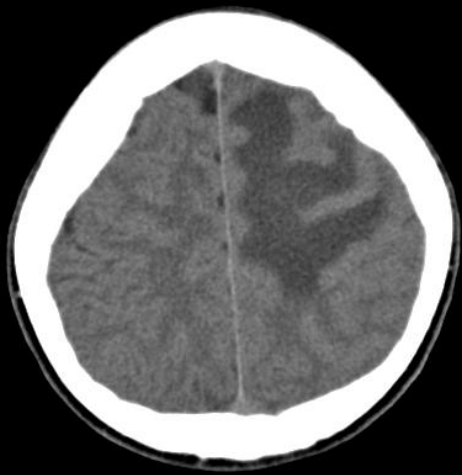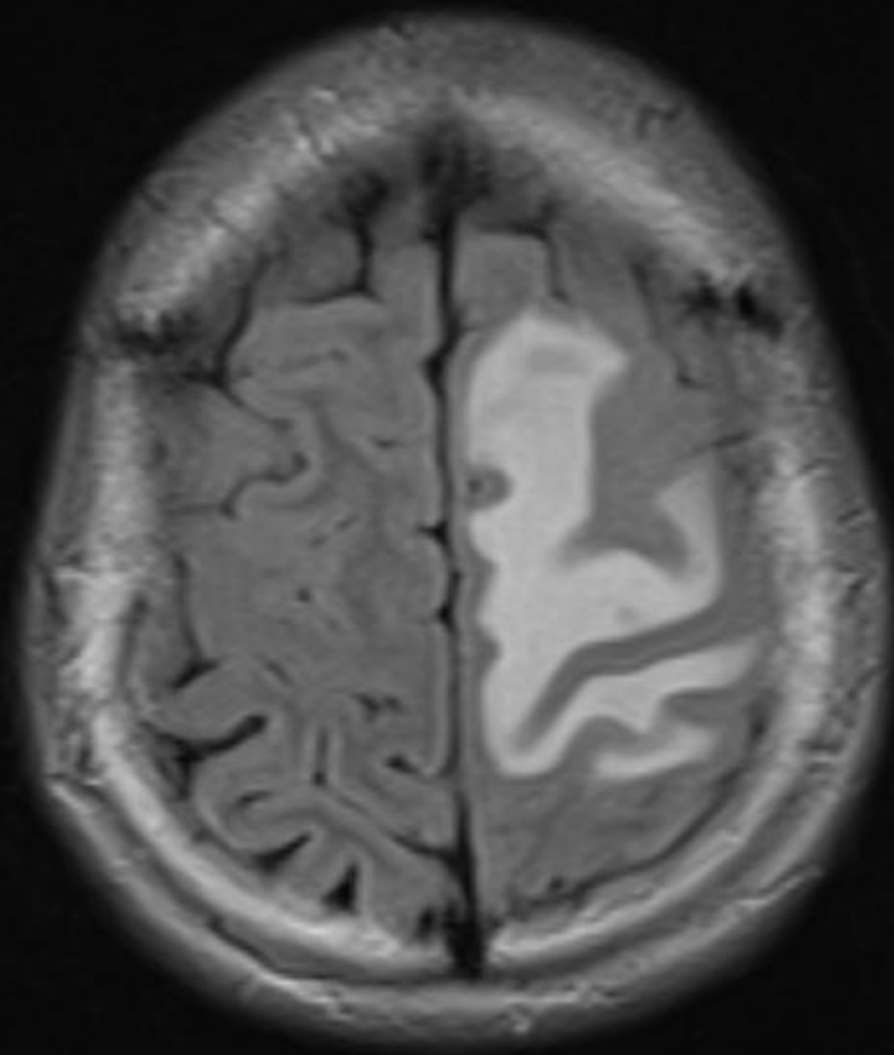
CT Head – November 2013

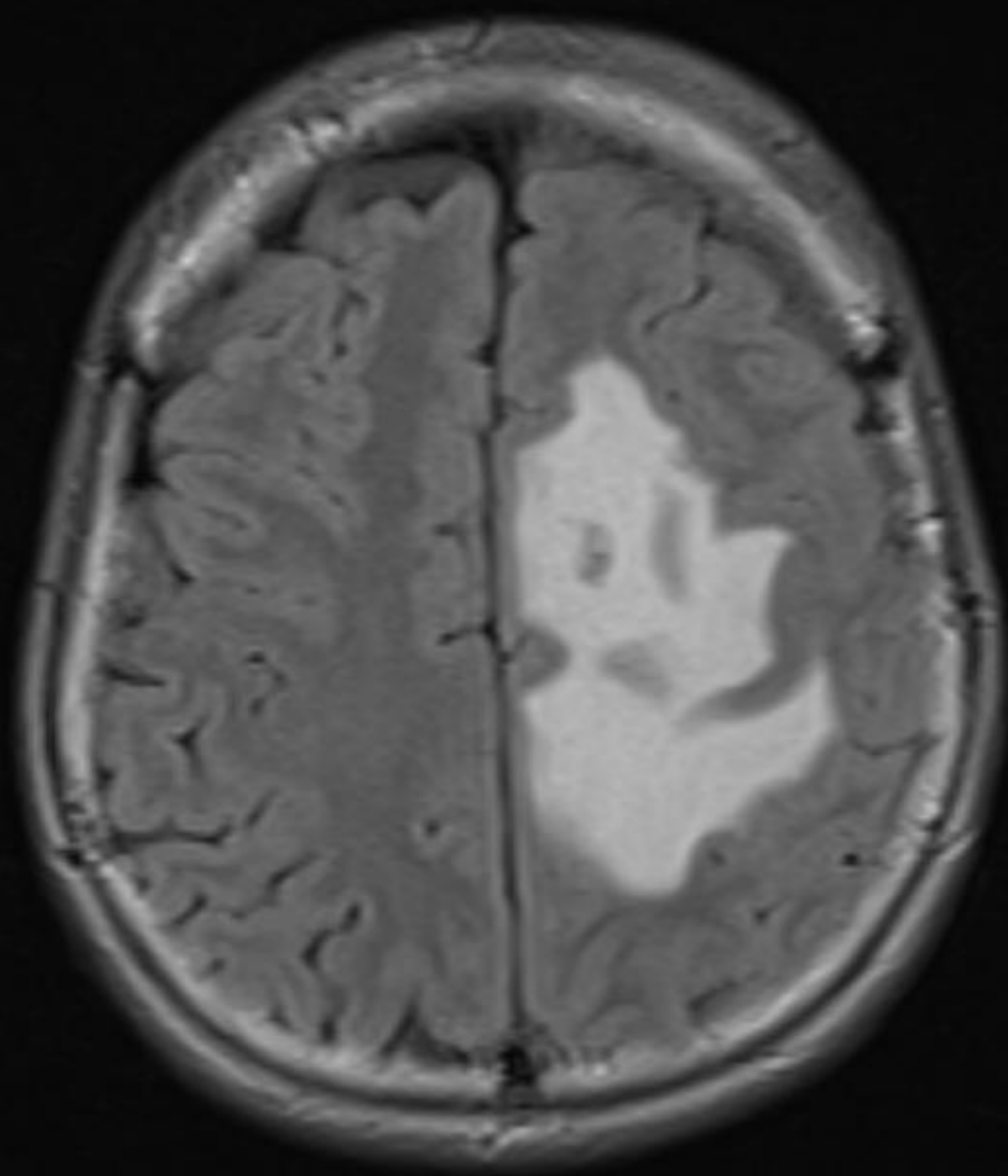


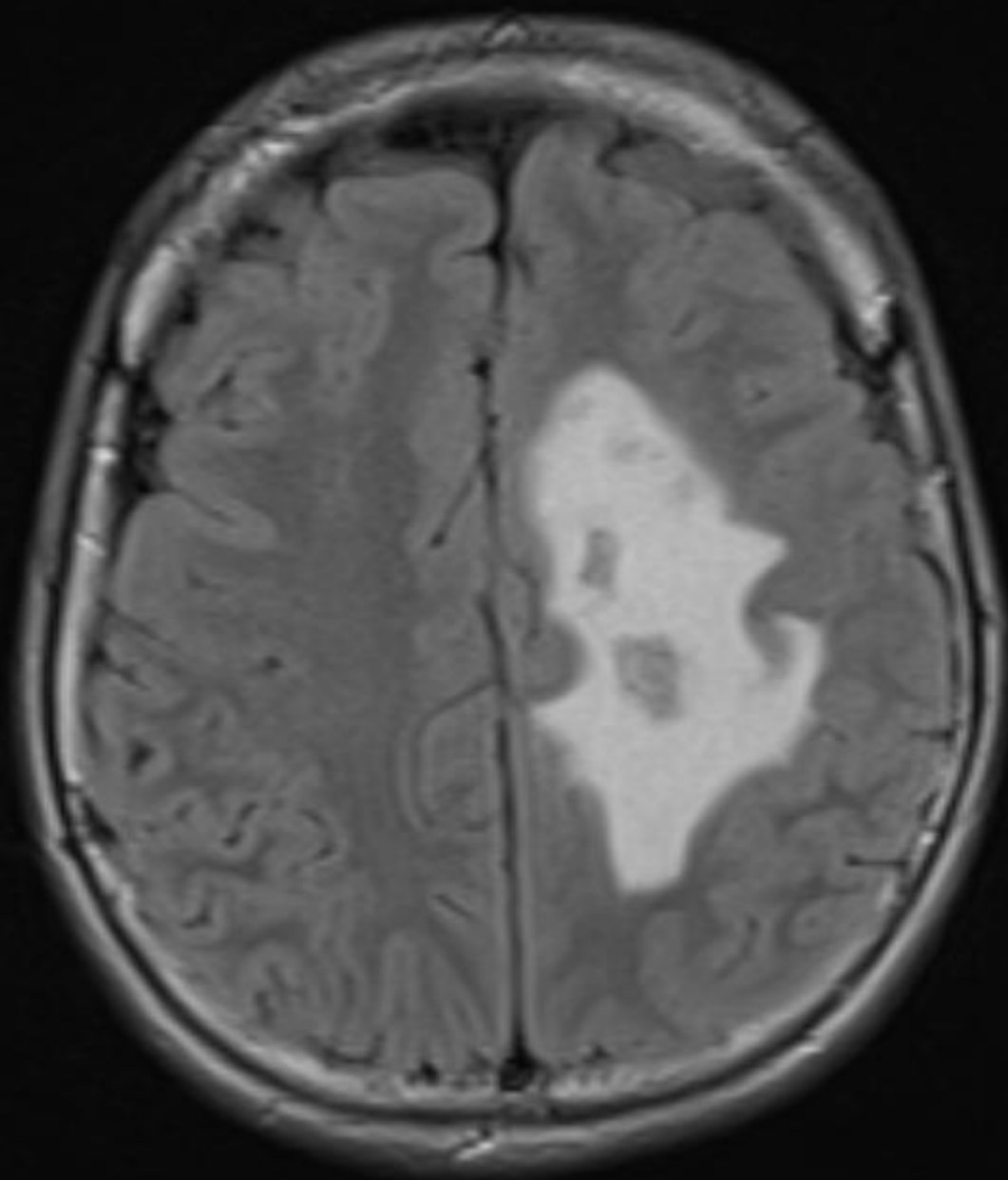


MRI – November 2013

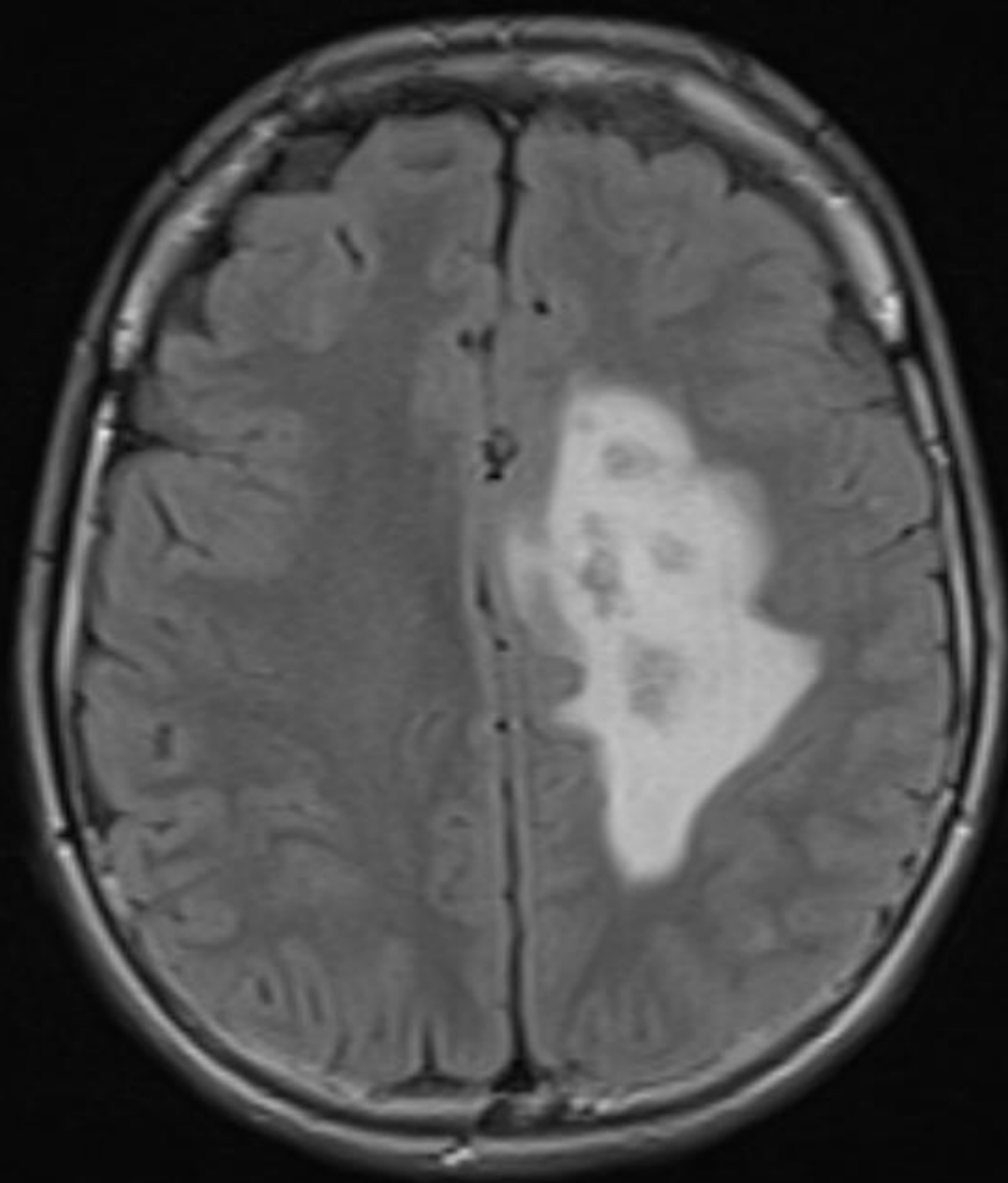
**Axial FLAIR**

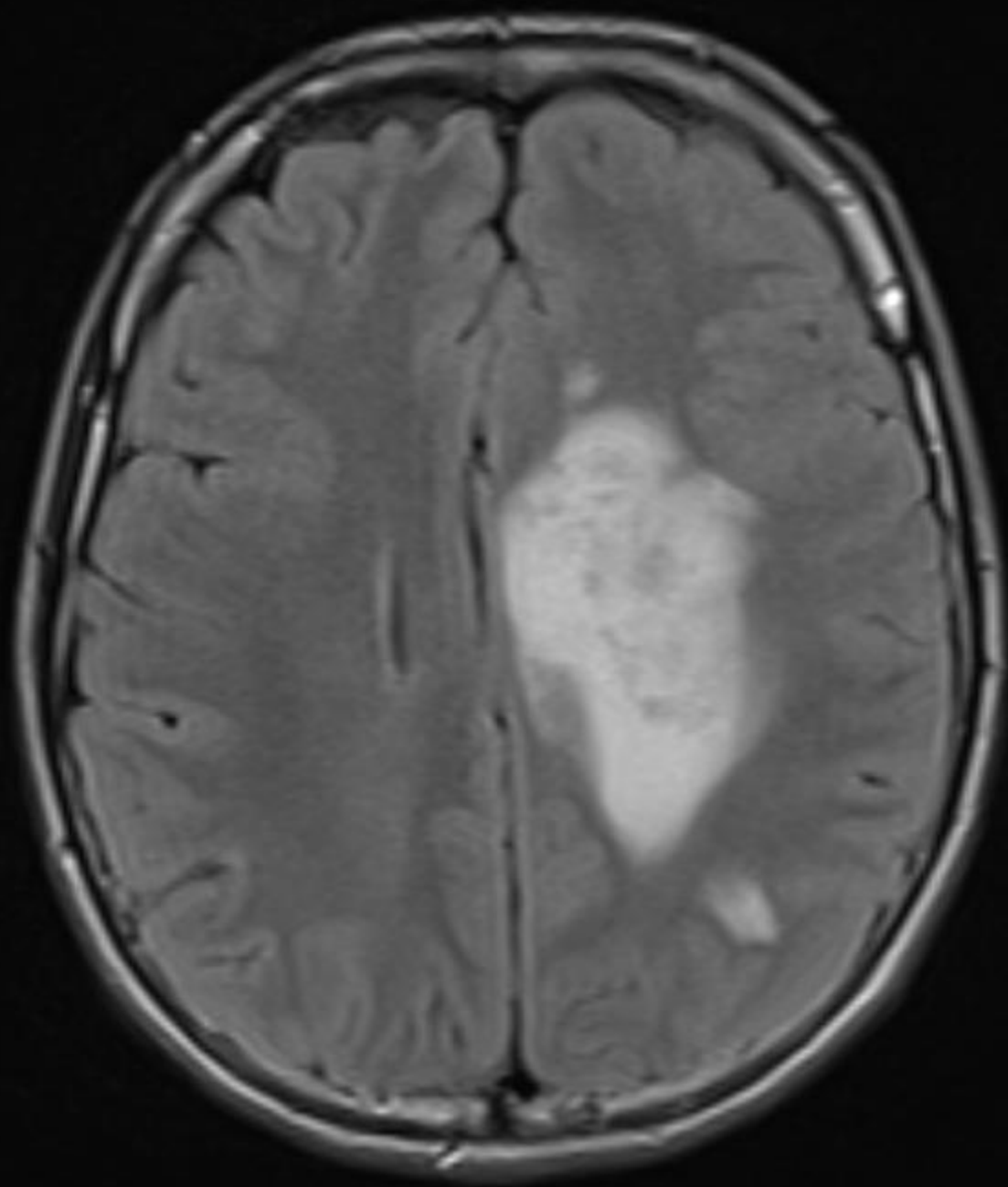


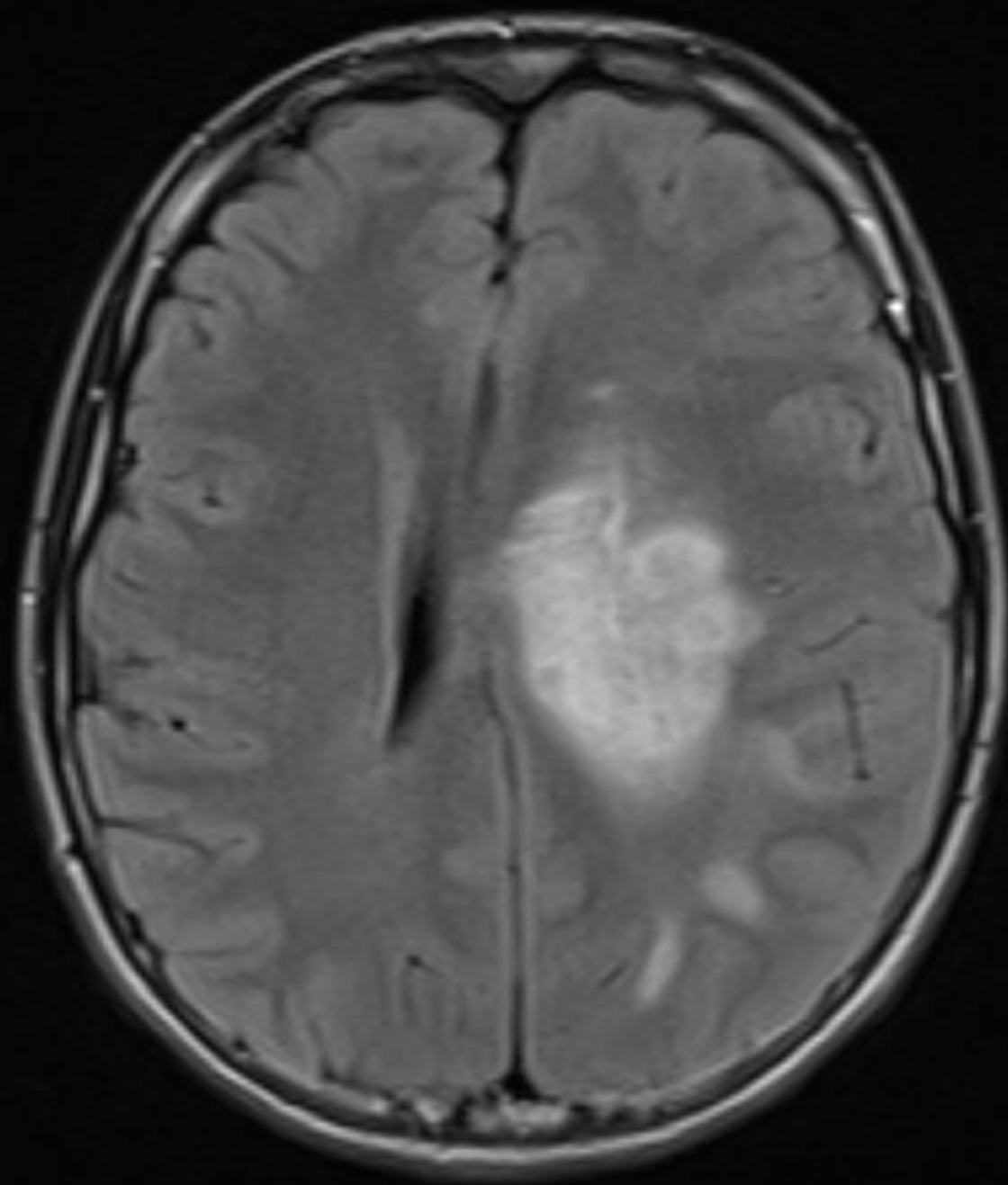


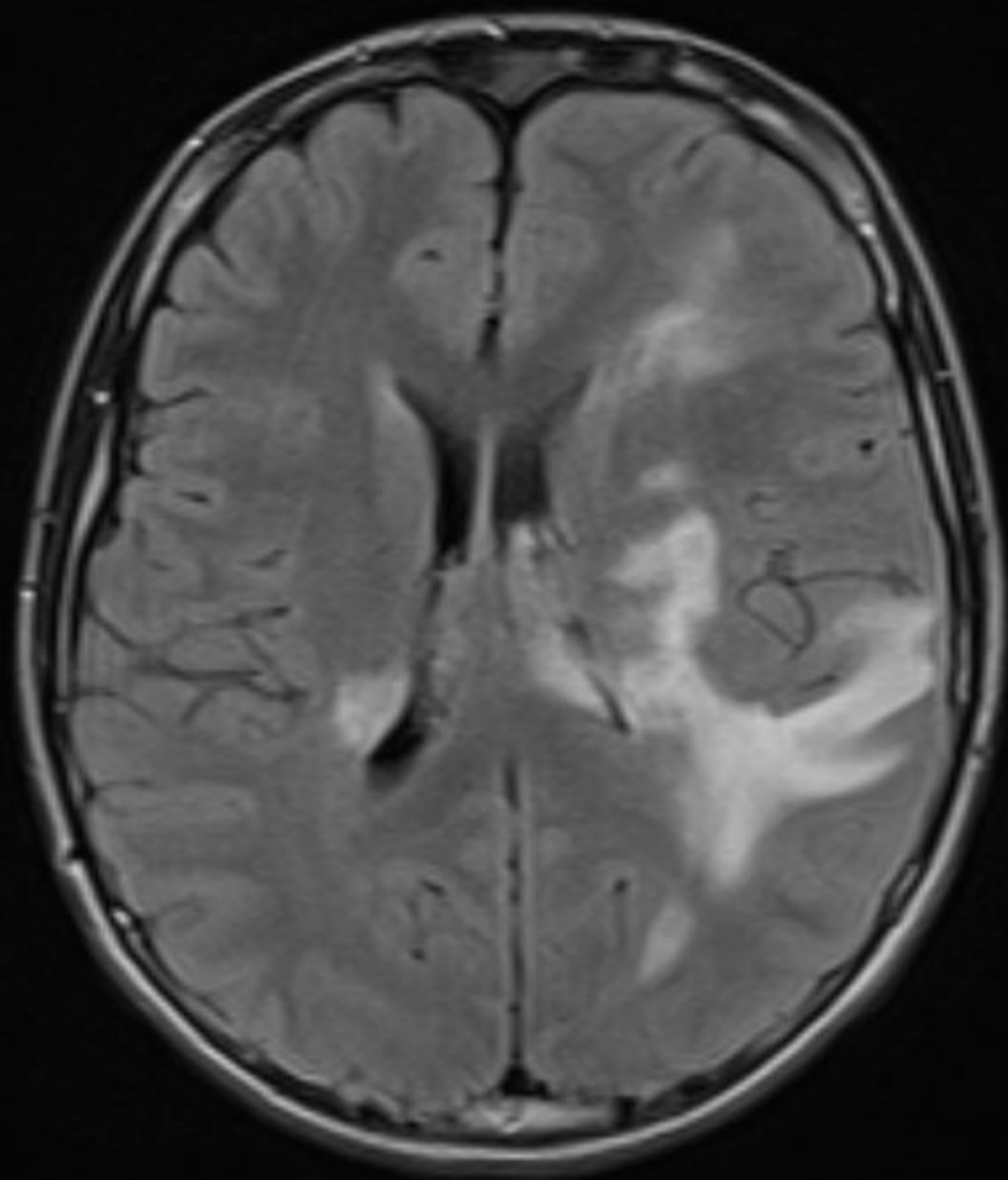


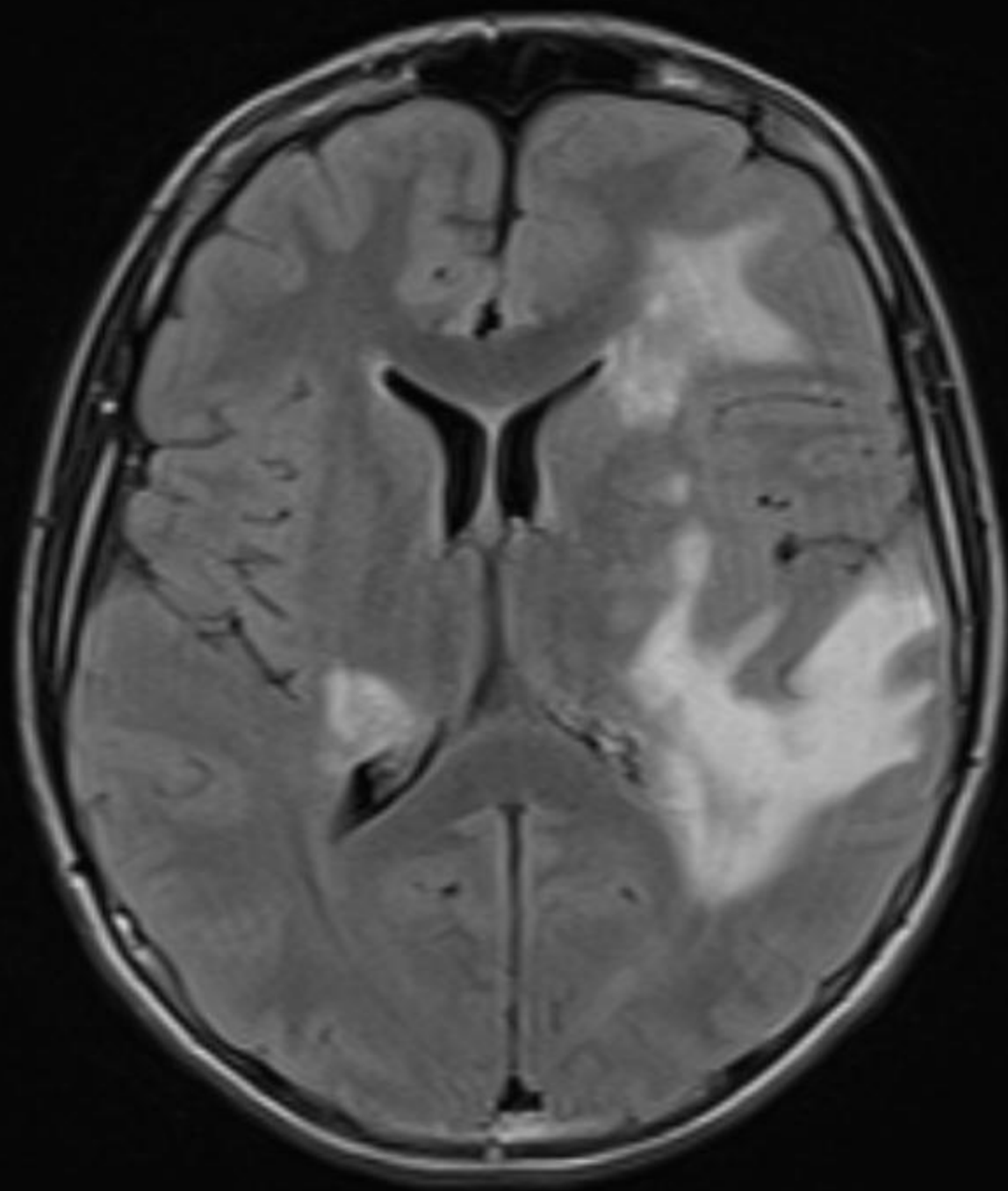


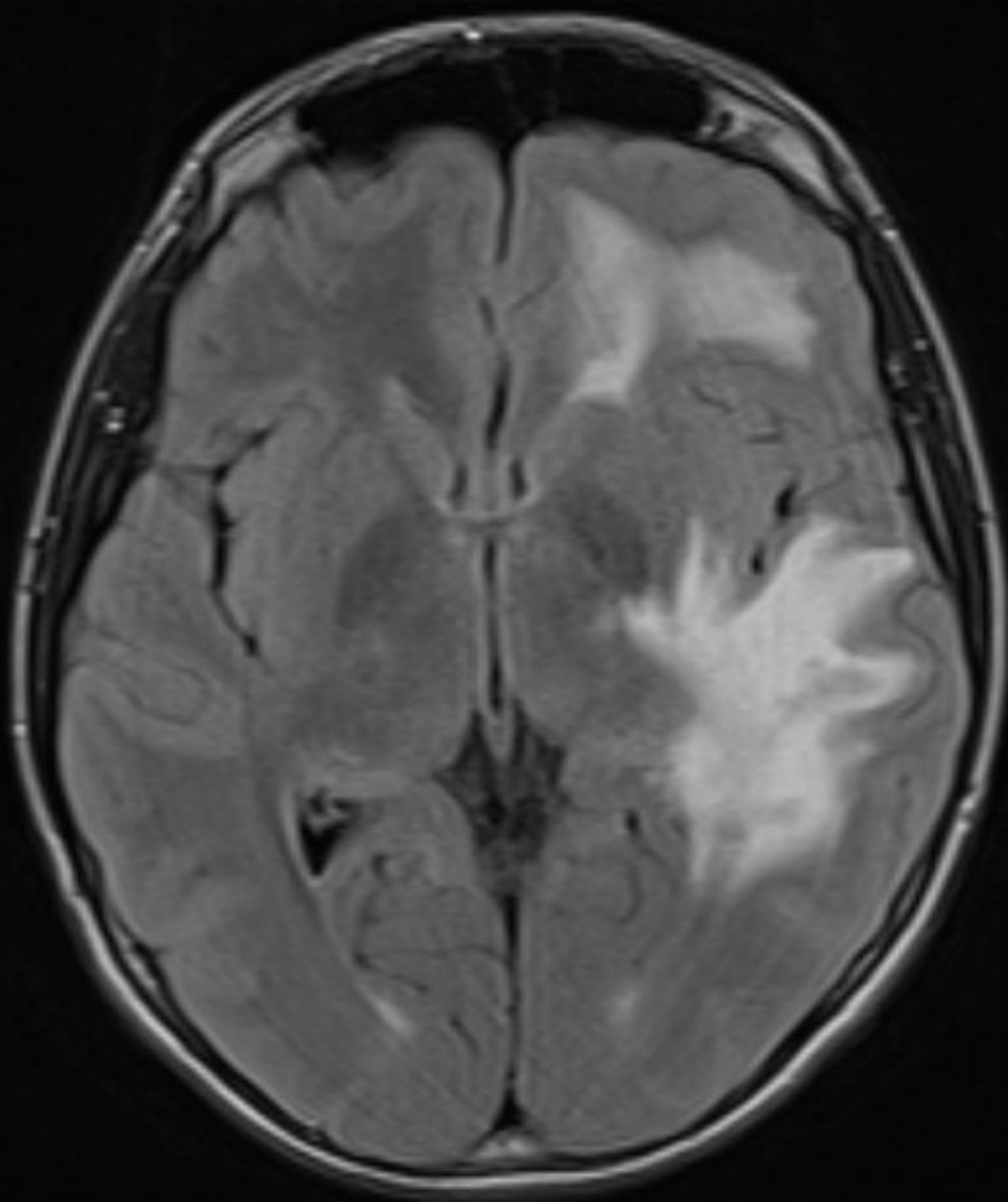


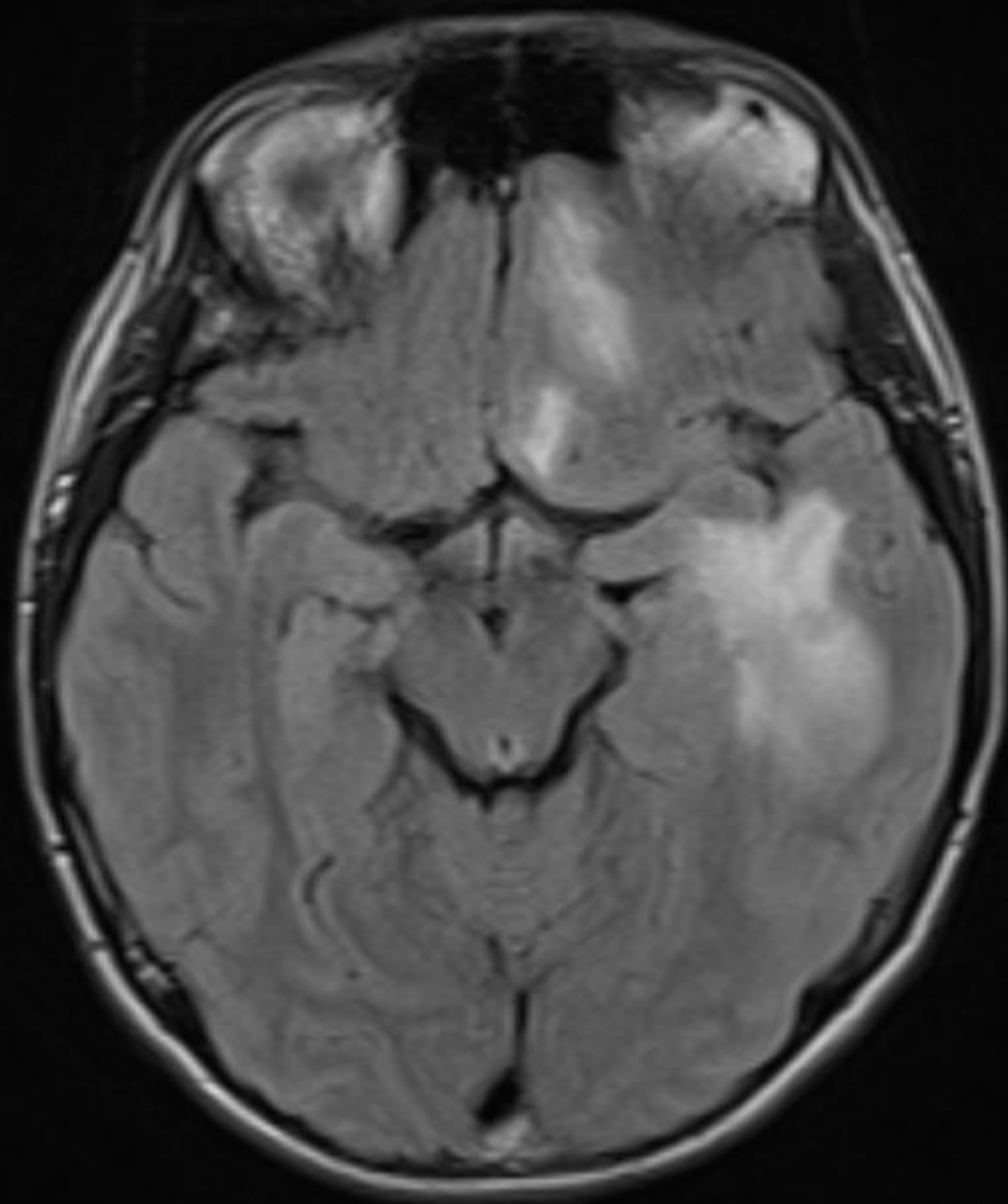


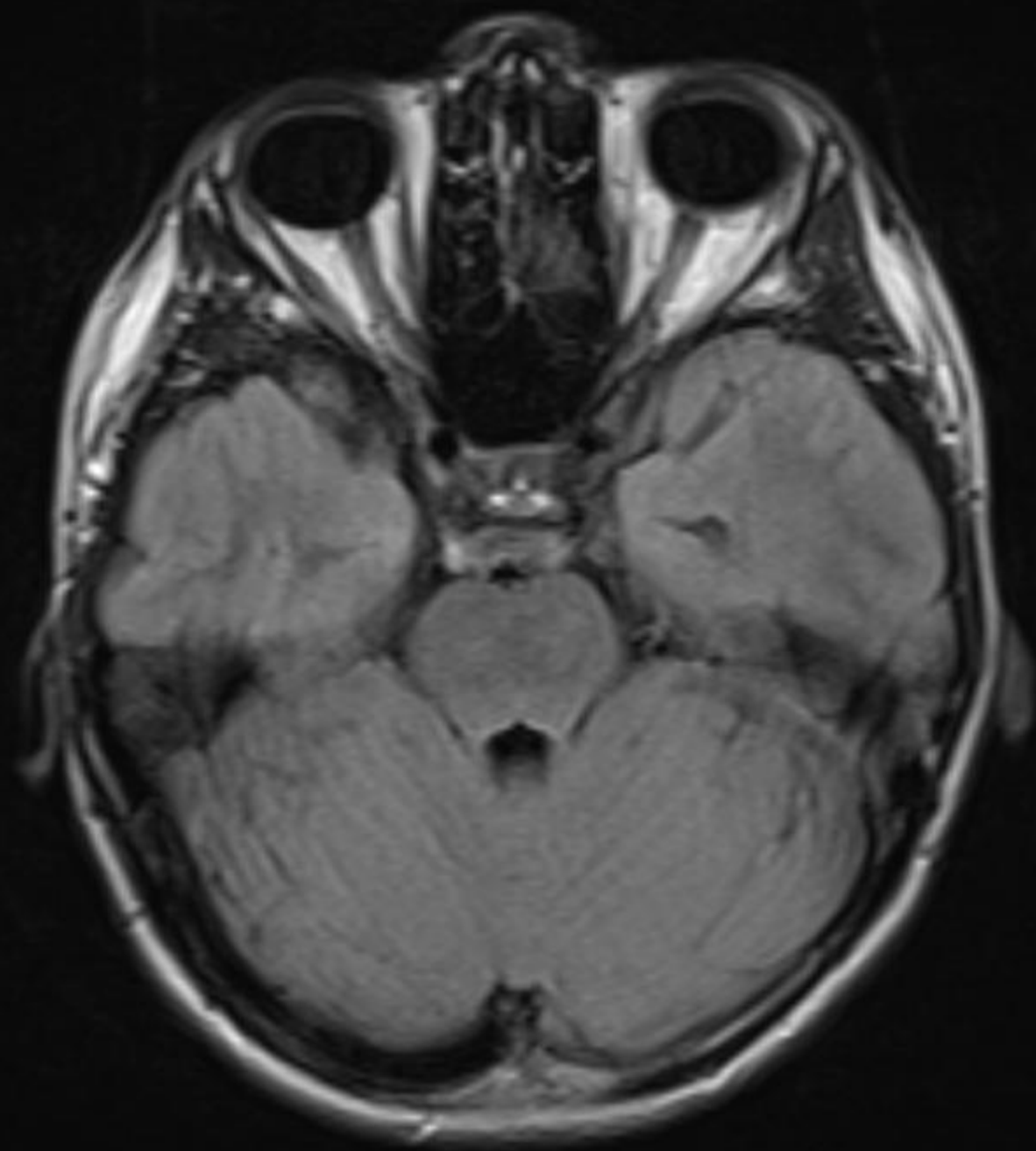




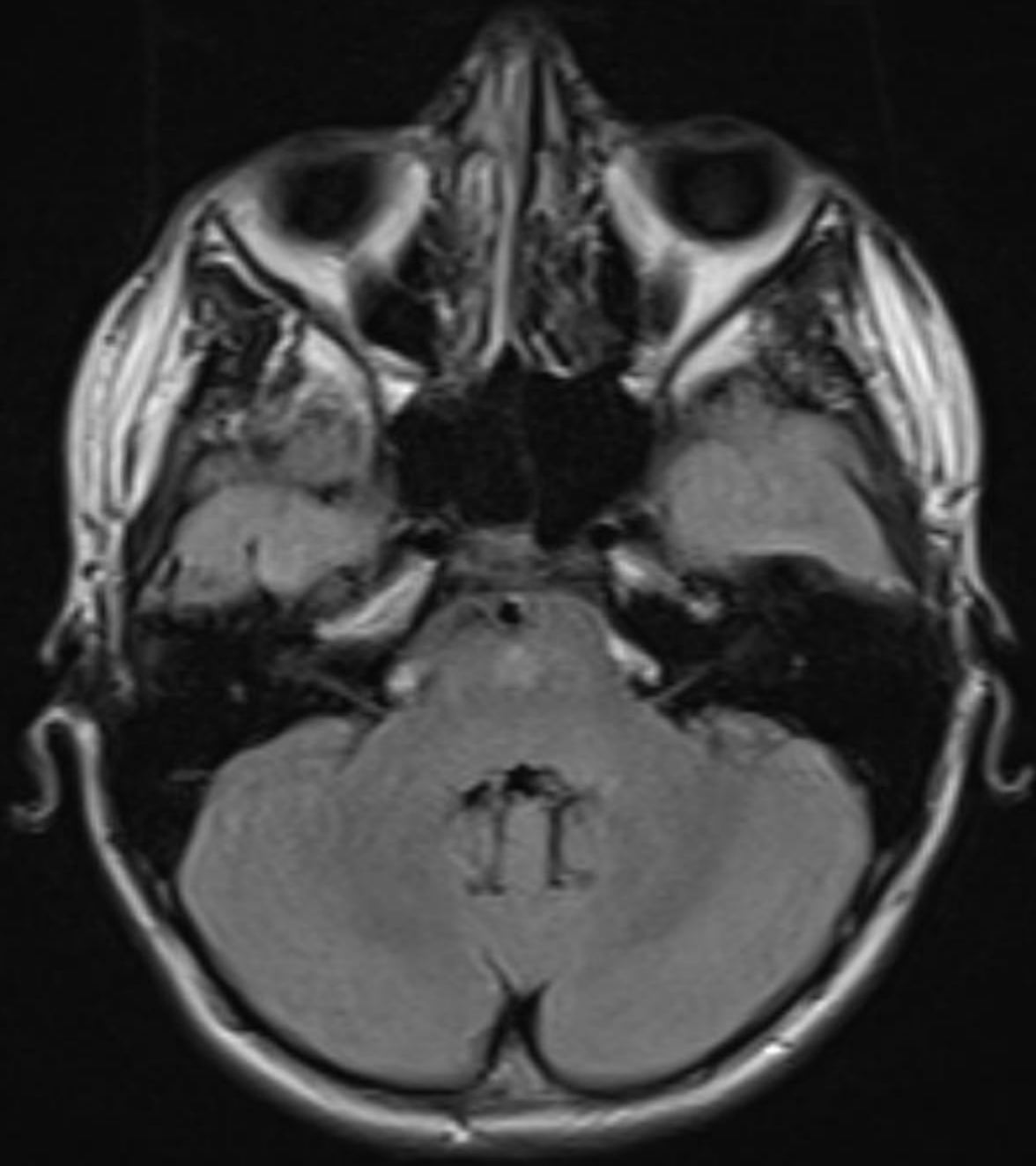




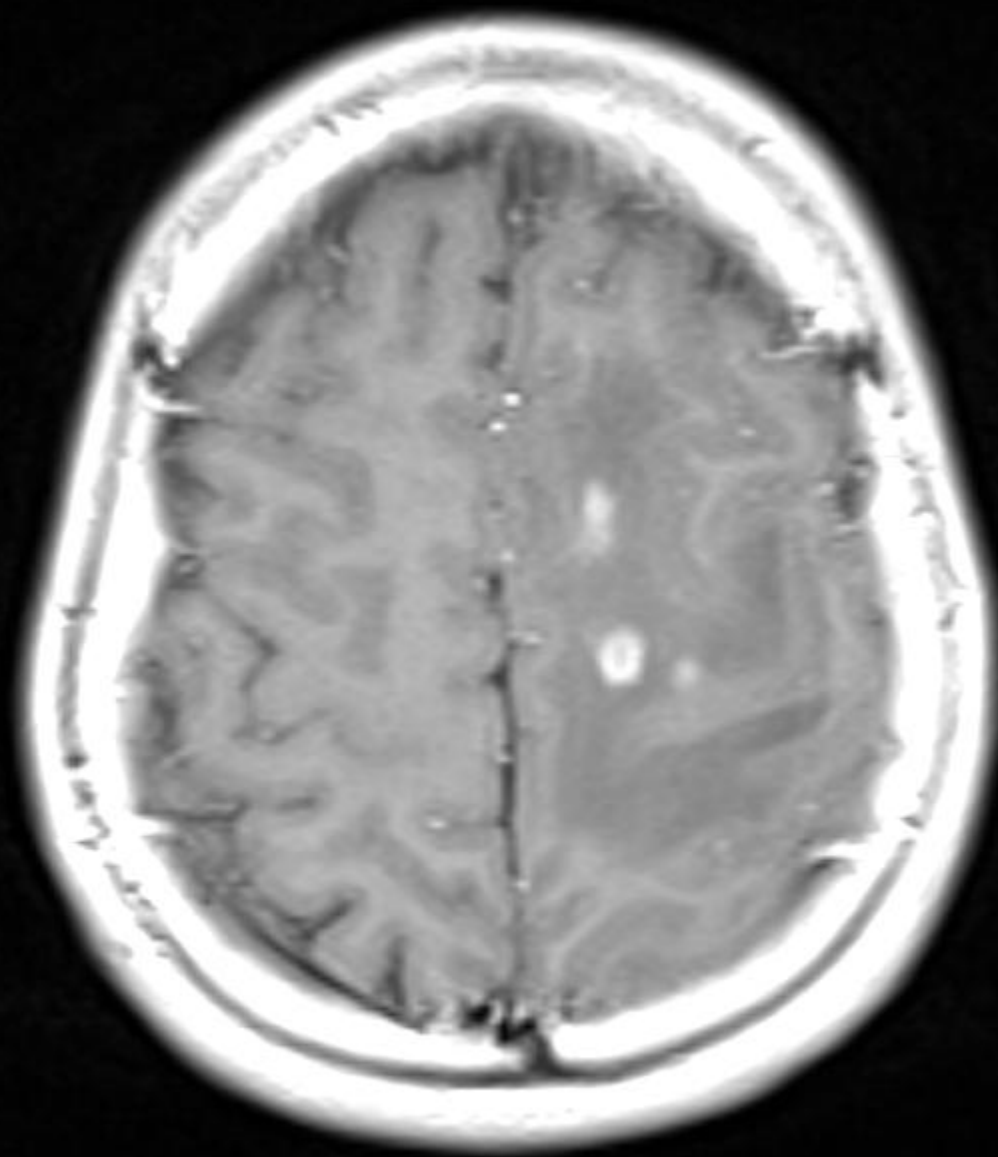


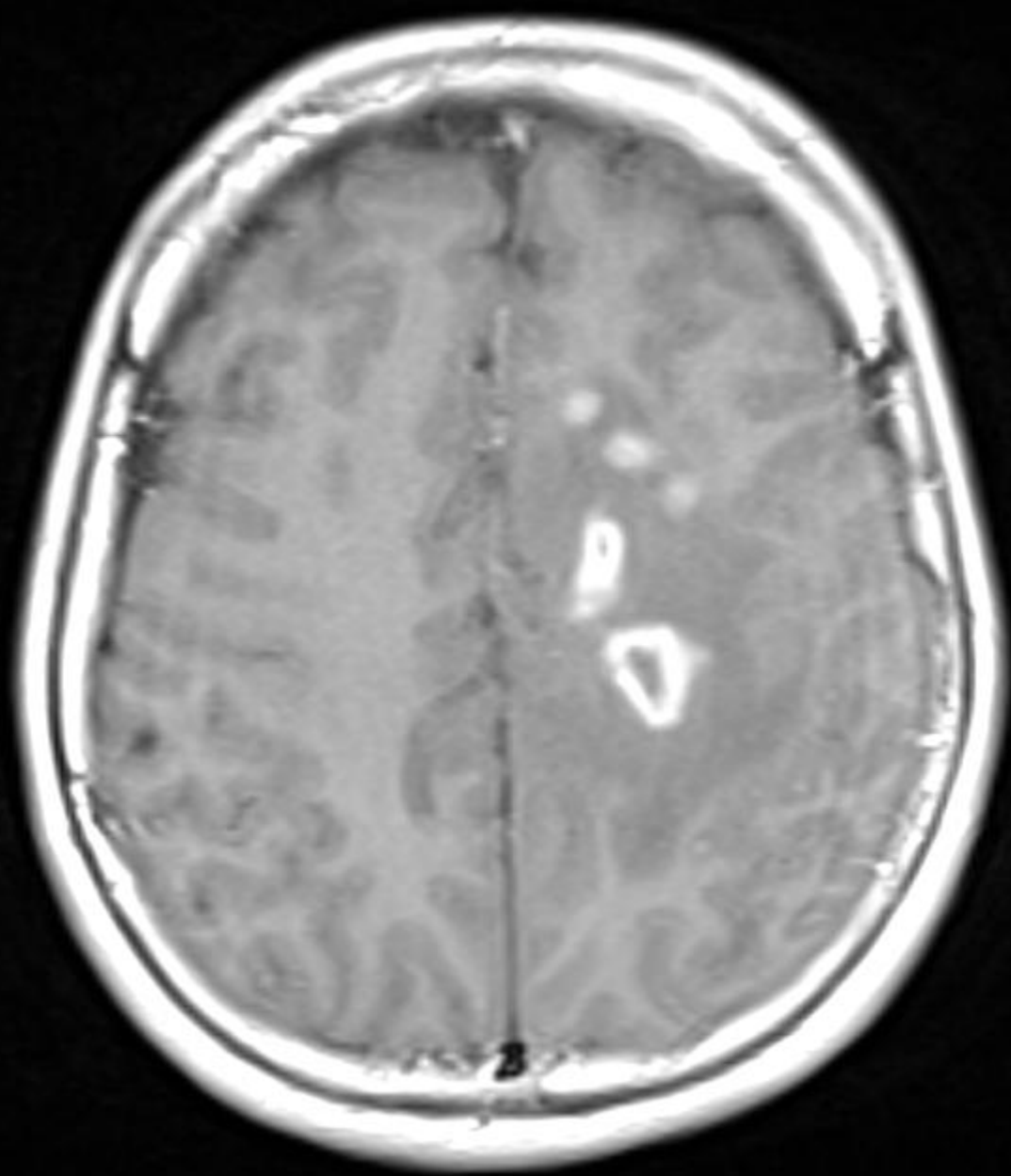


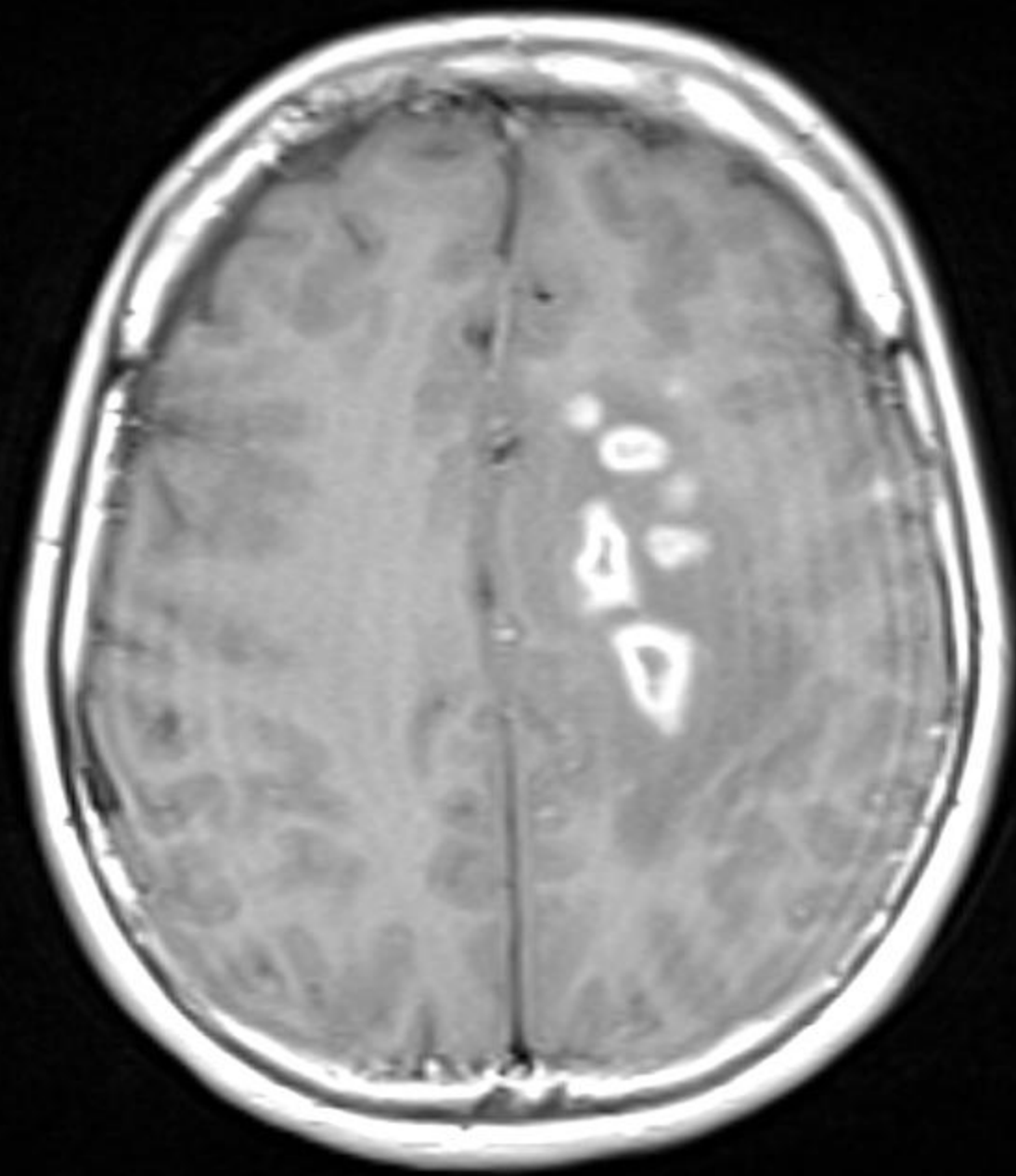


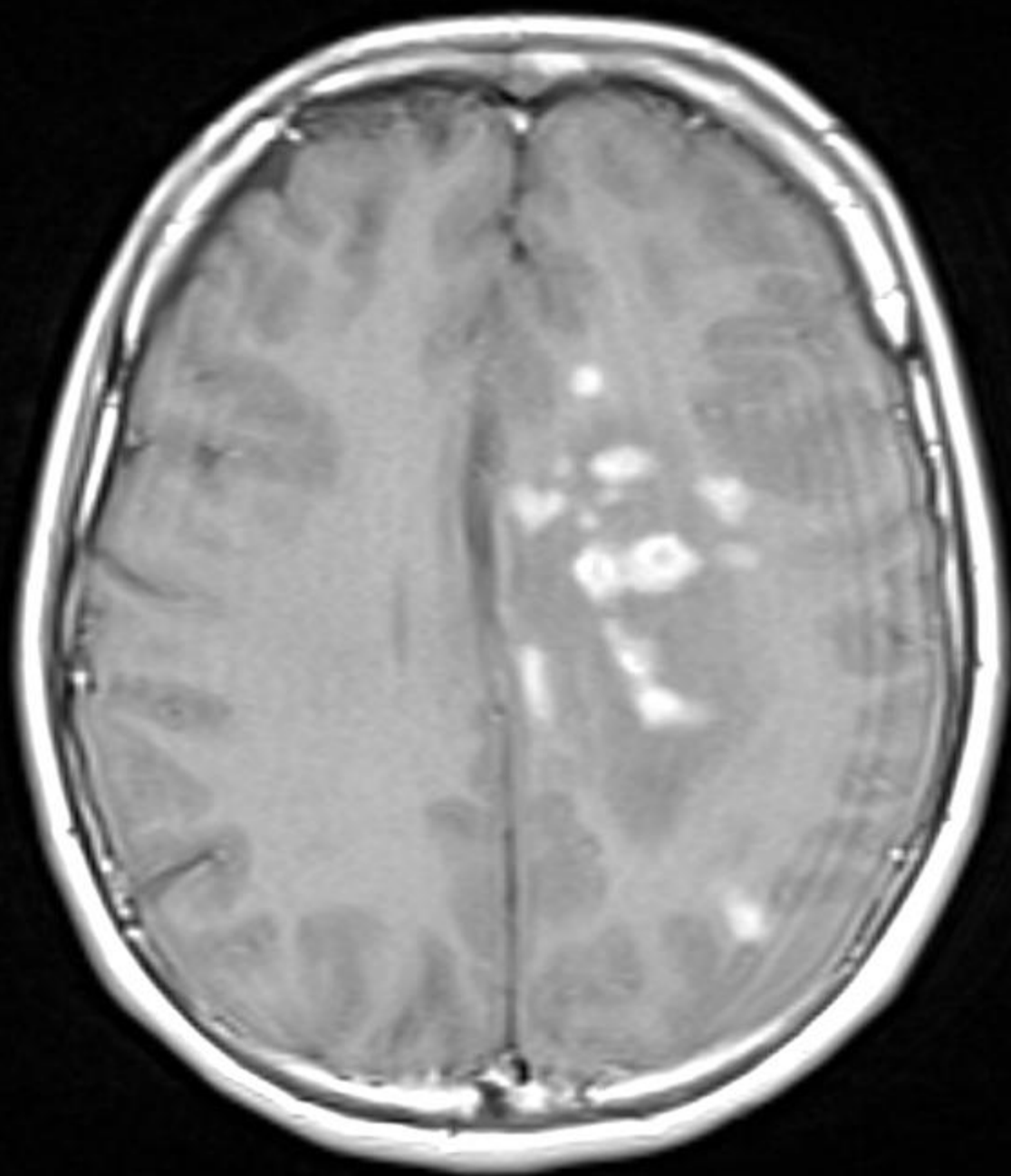


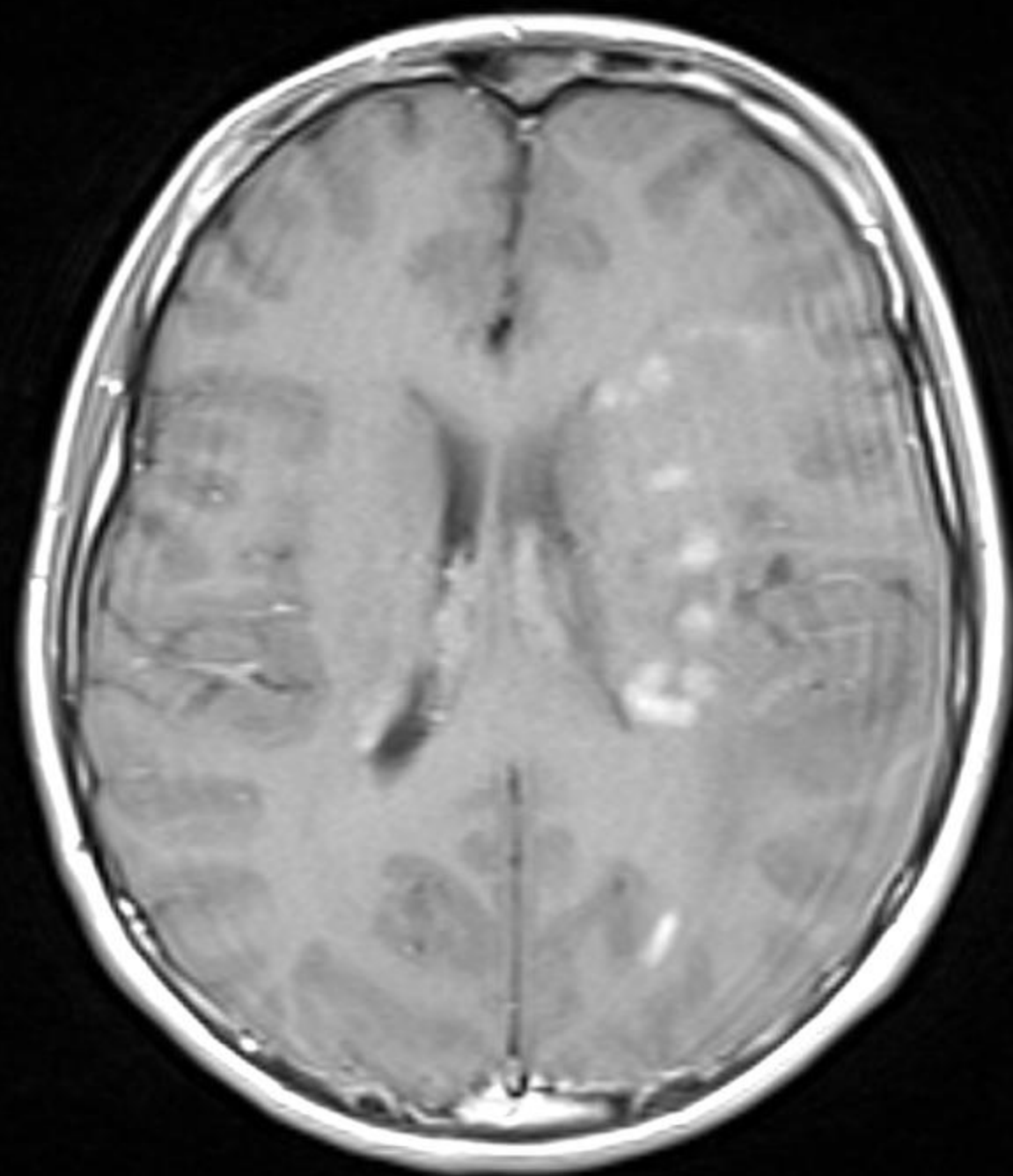
**Axial T1 Post Gad**

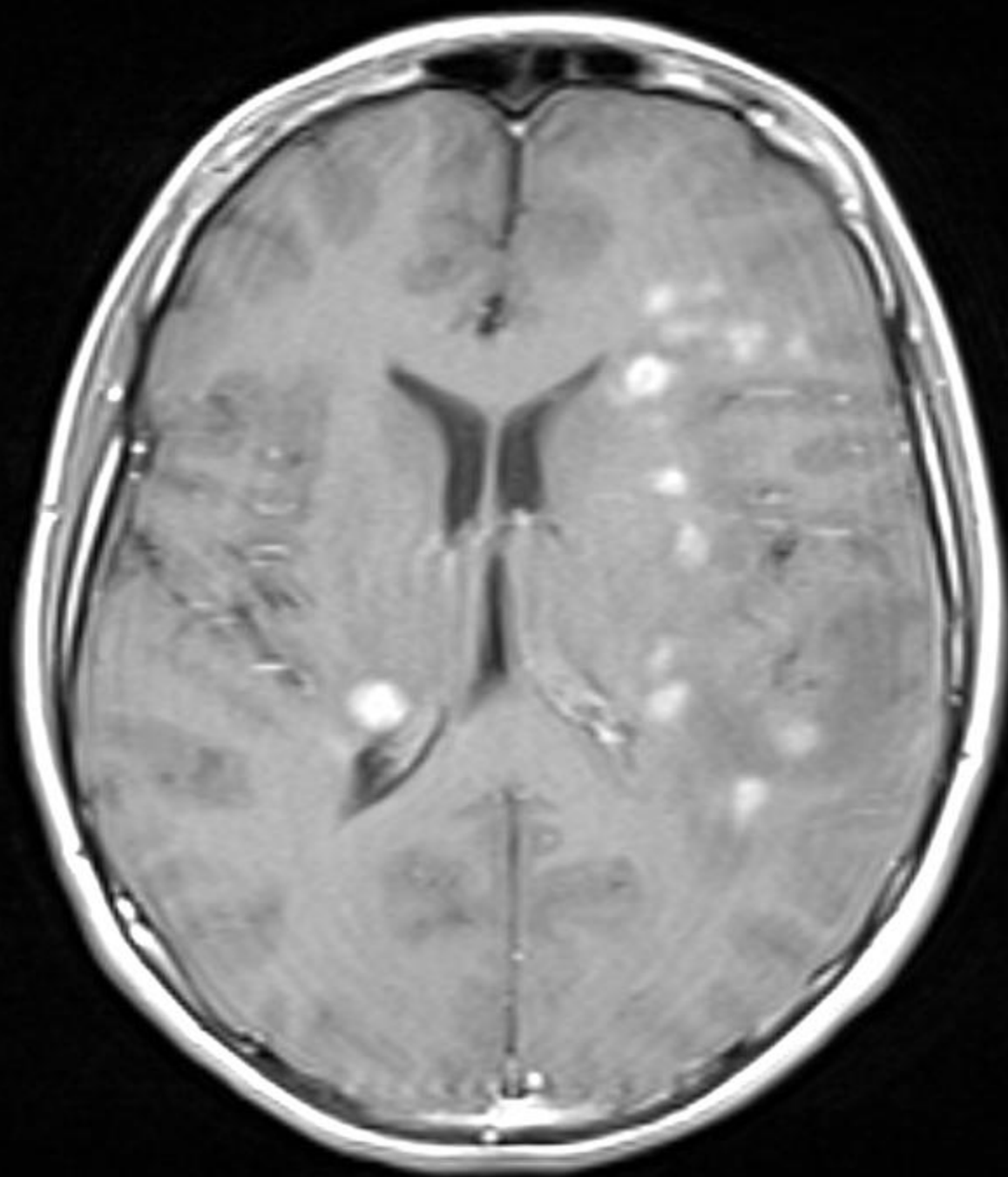




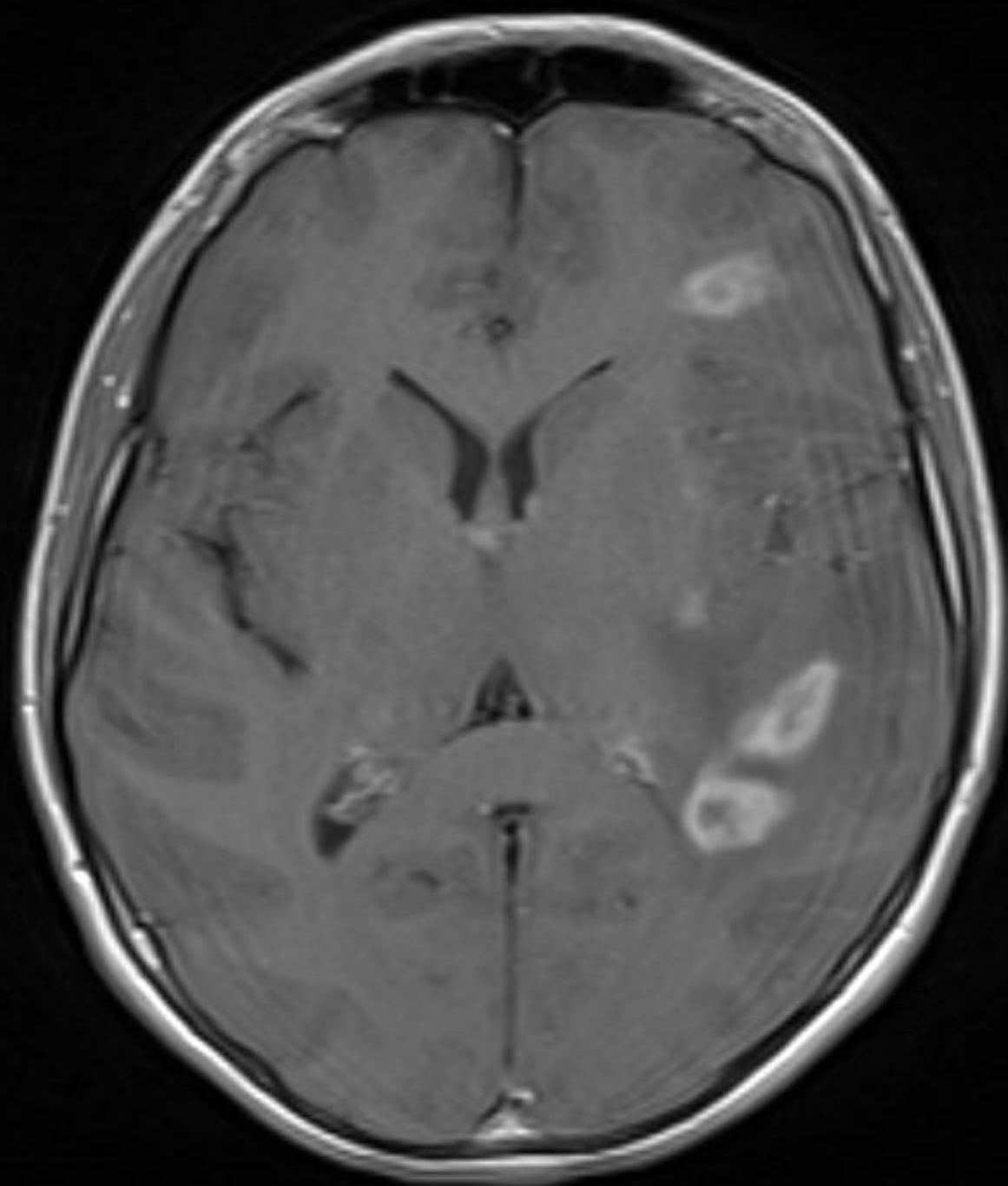


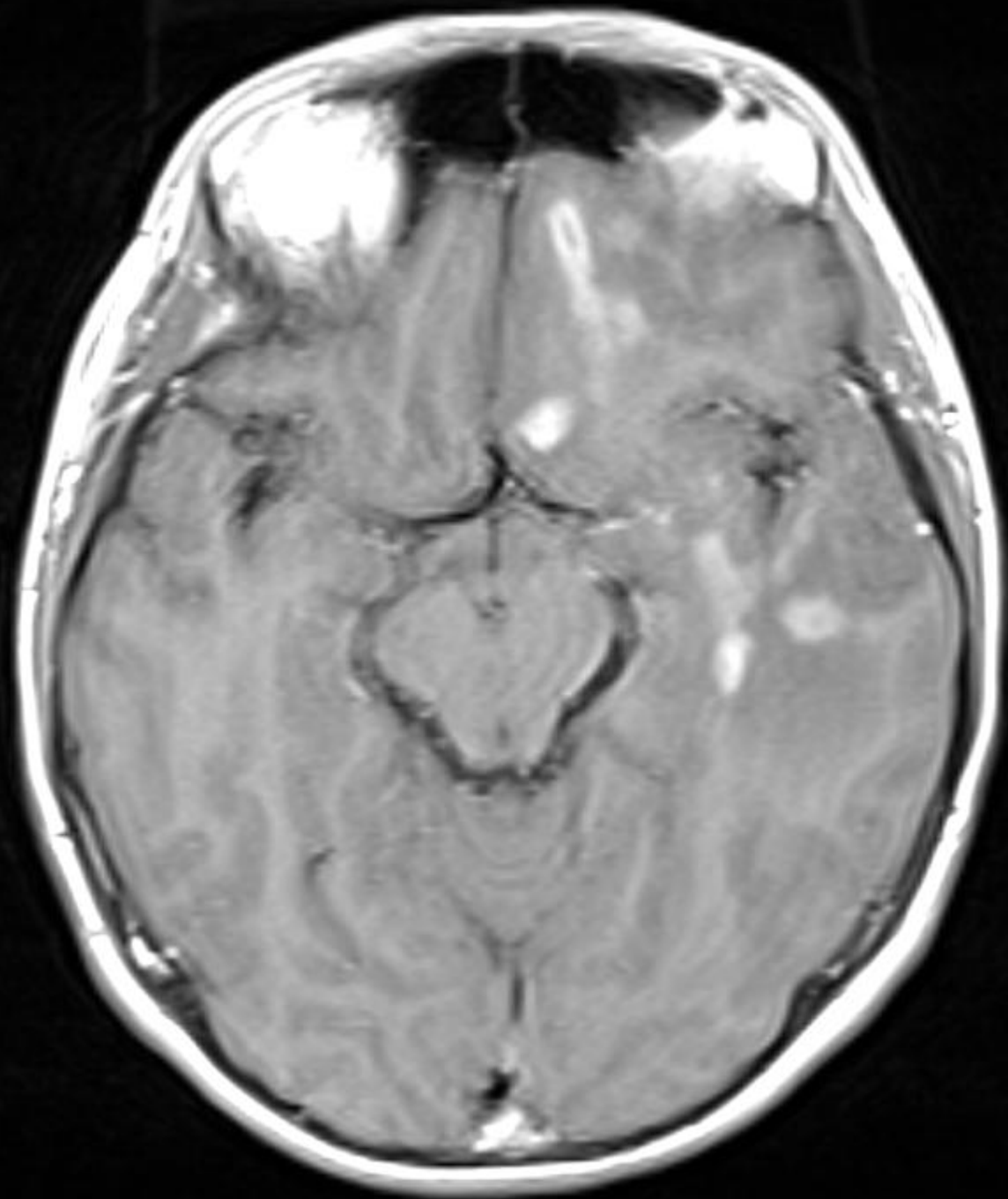




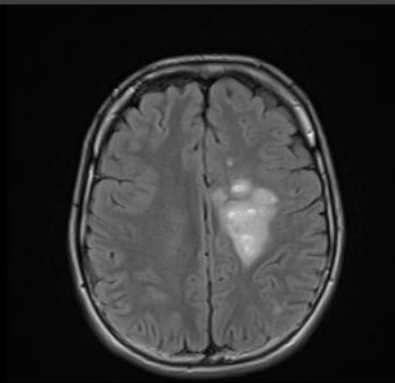
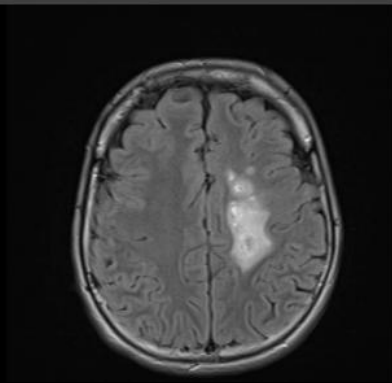
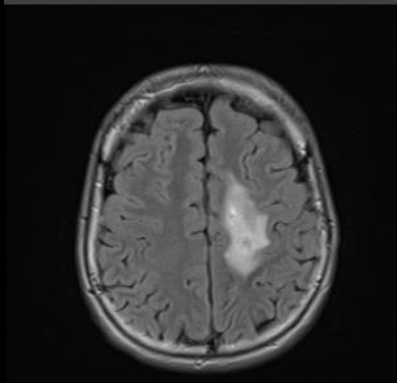
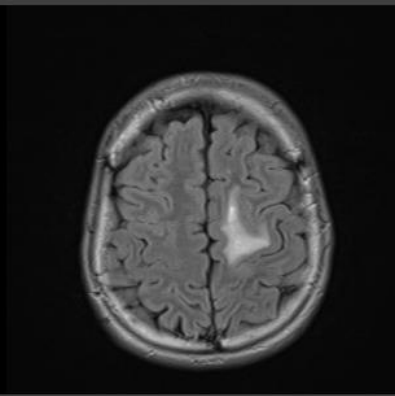
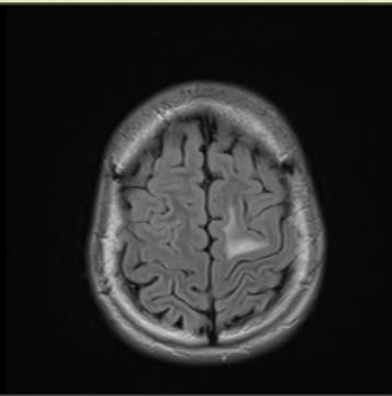
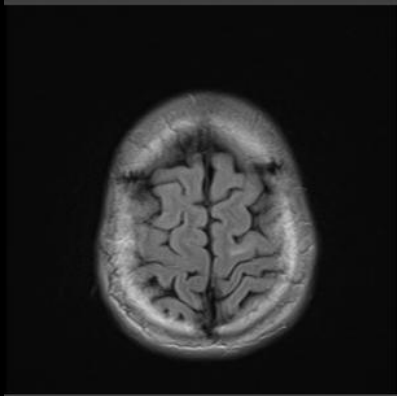
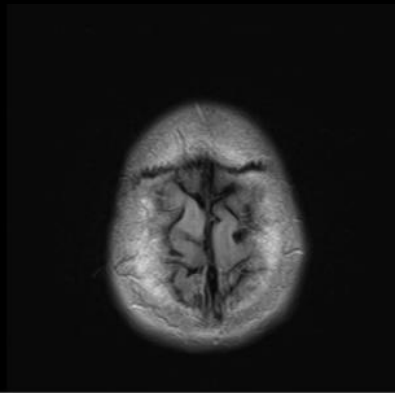
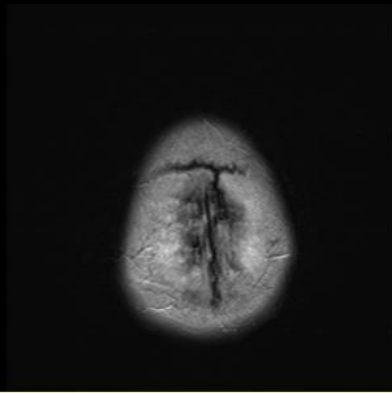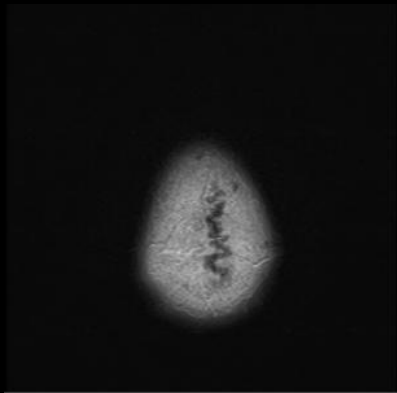


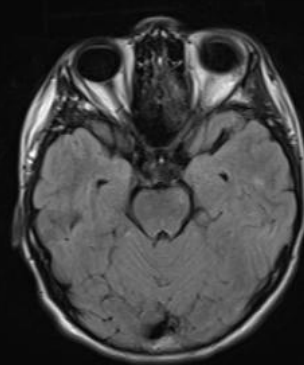
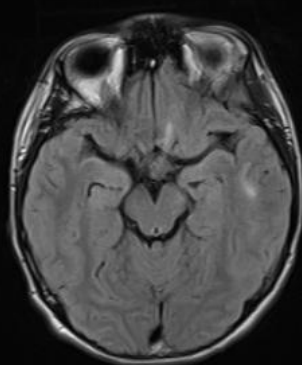
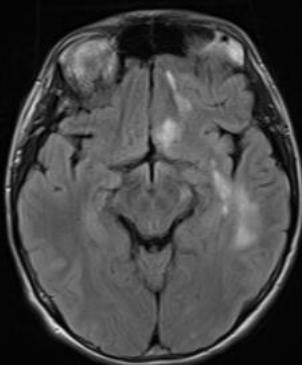
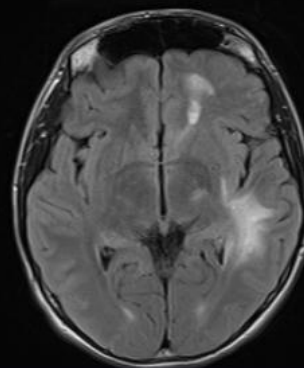
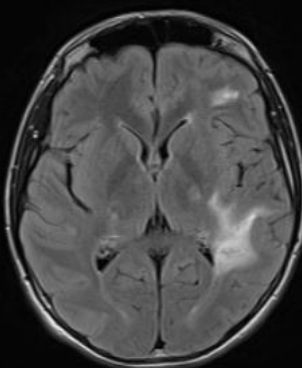
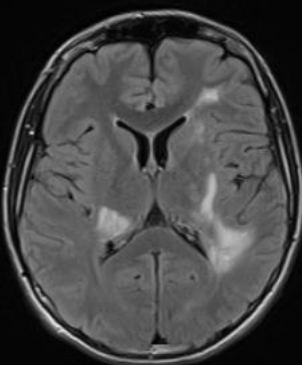
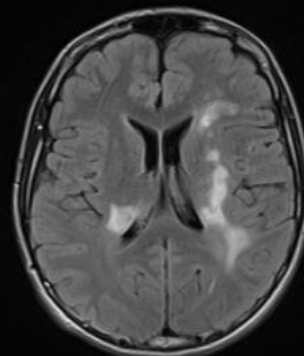
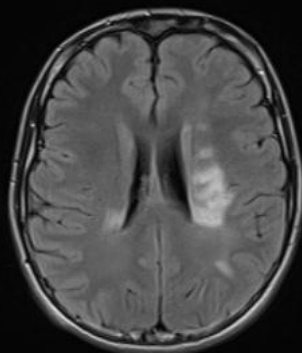
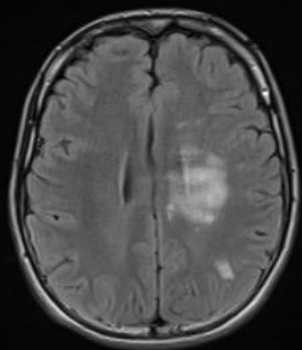


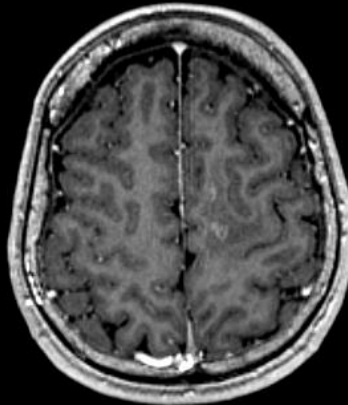
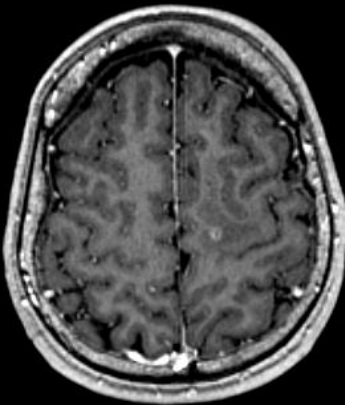
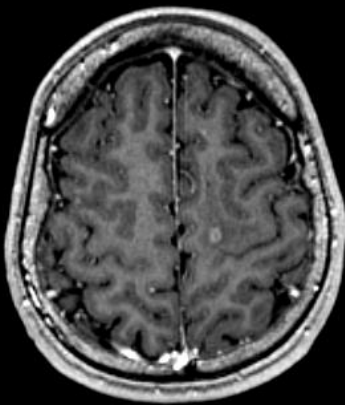
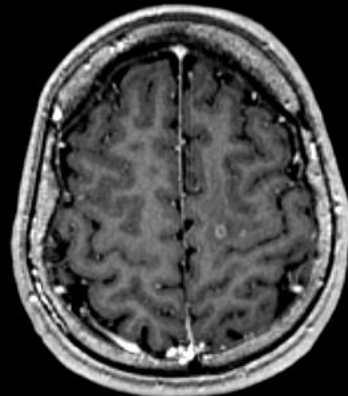
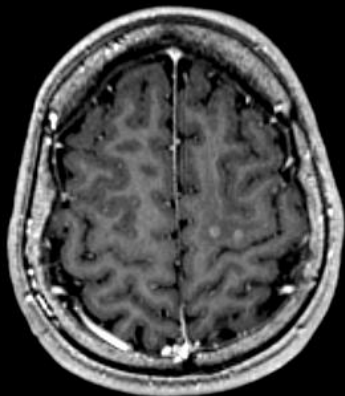
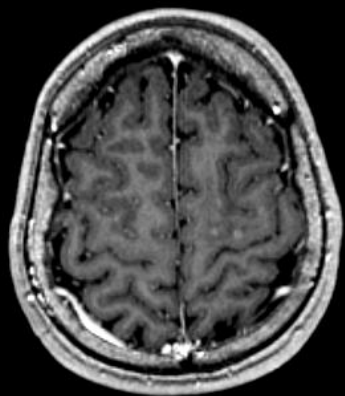


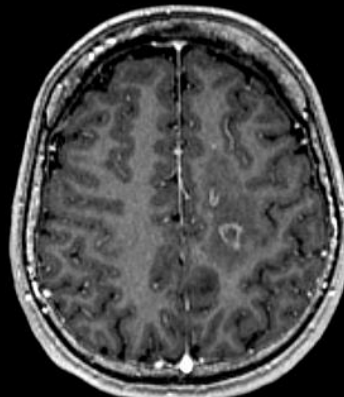
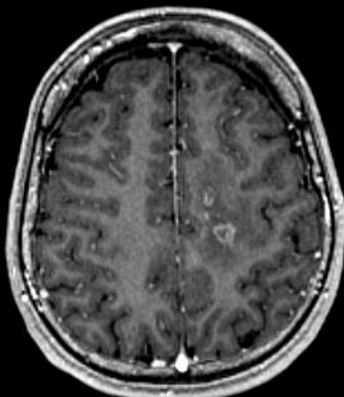
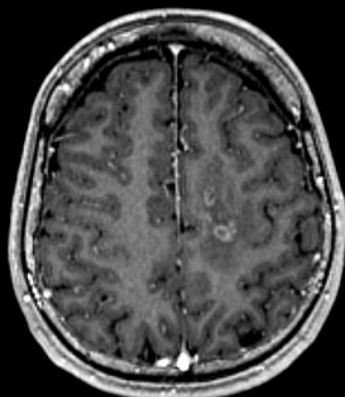
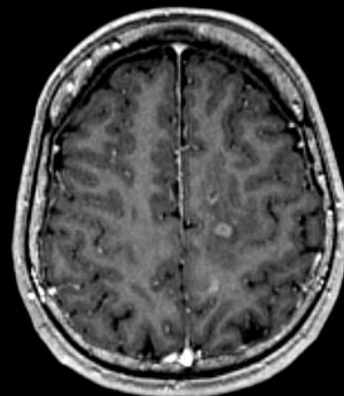
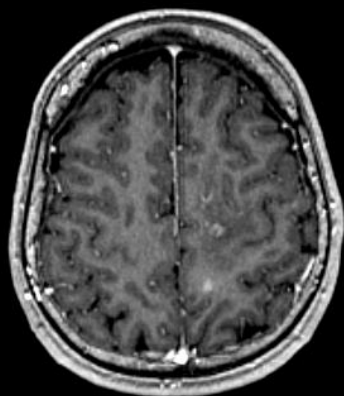
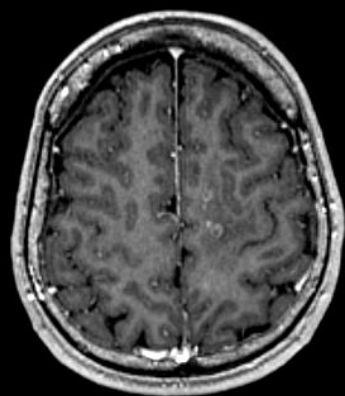


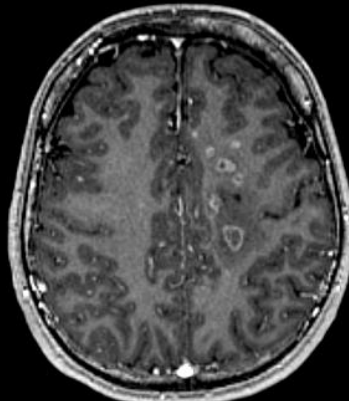
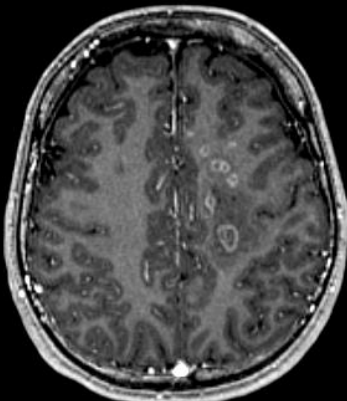
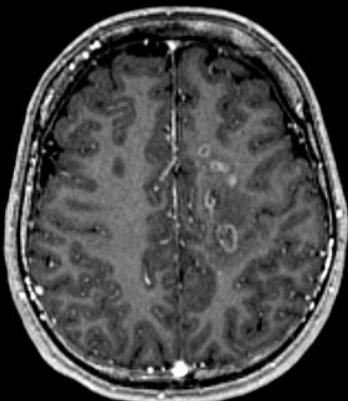
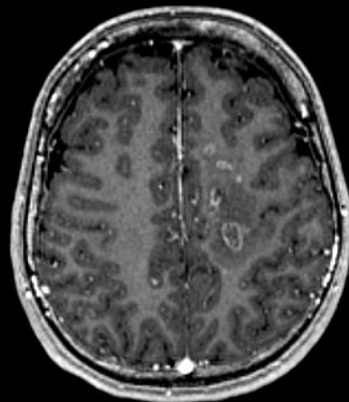
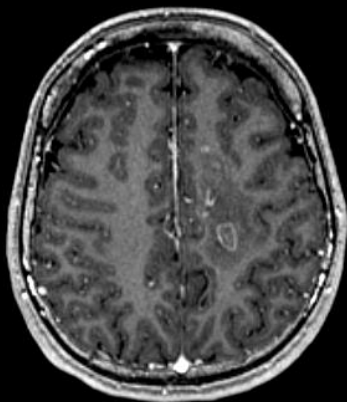
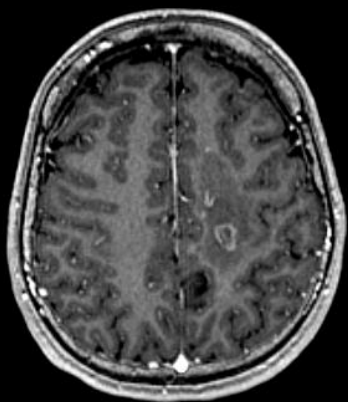
MRI – December 2013



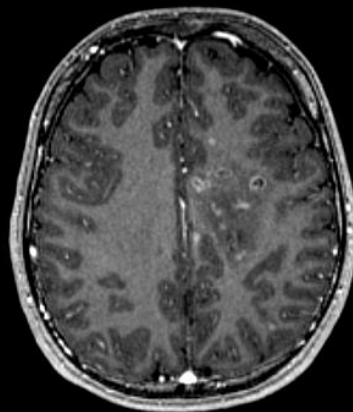
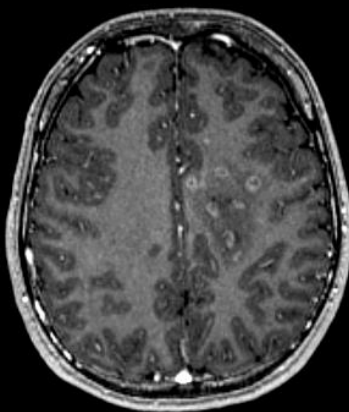
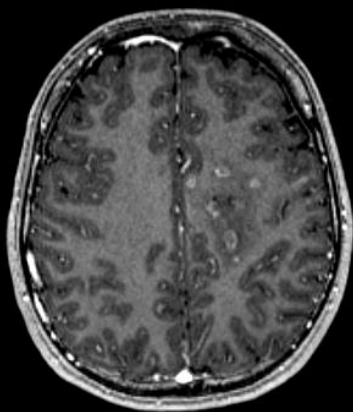
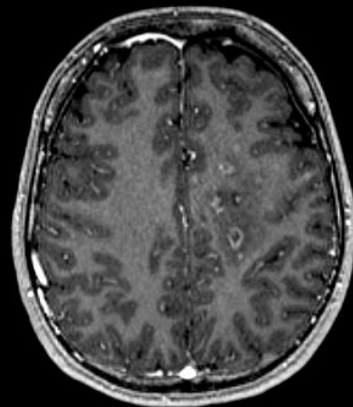
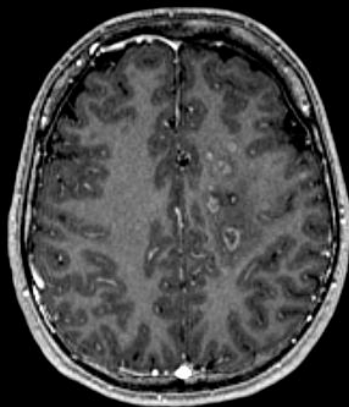
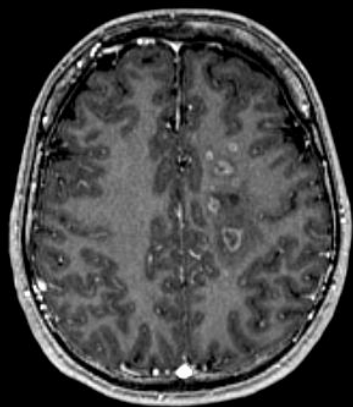




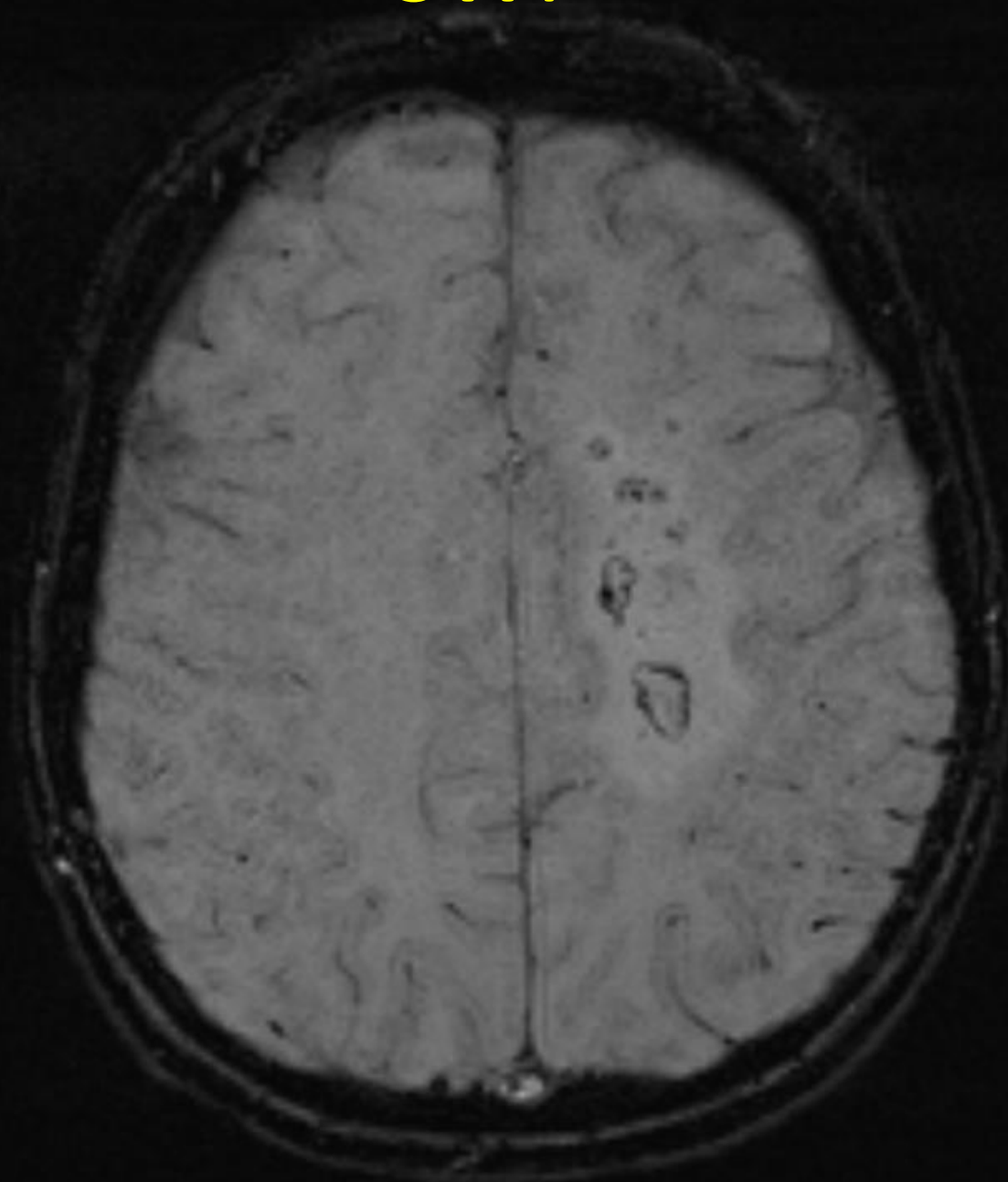




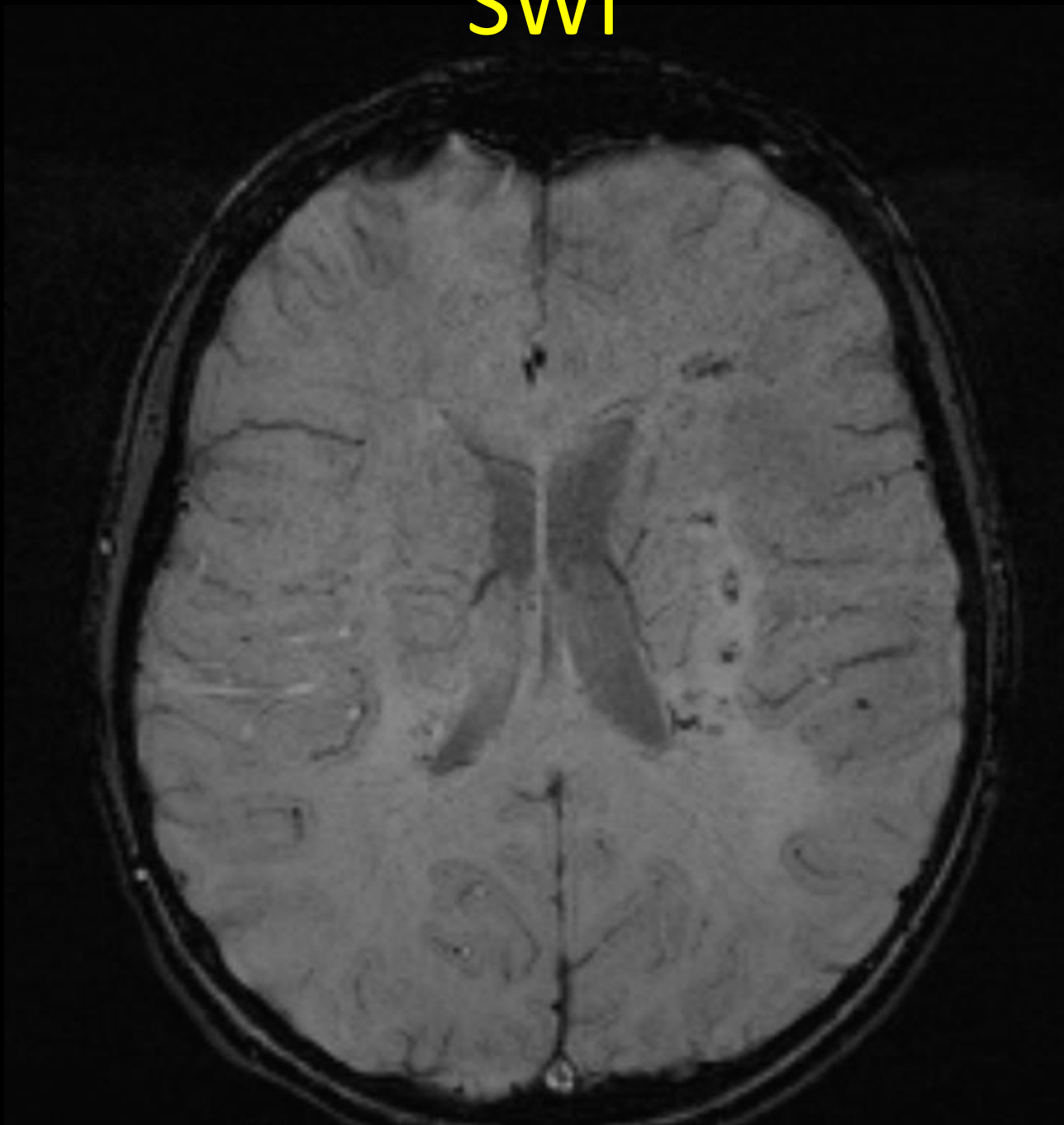




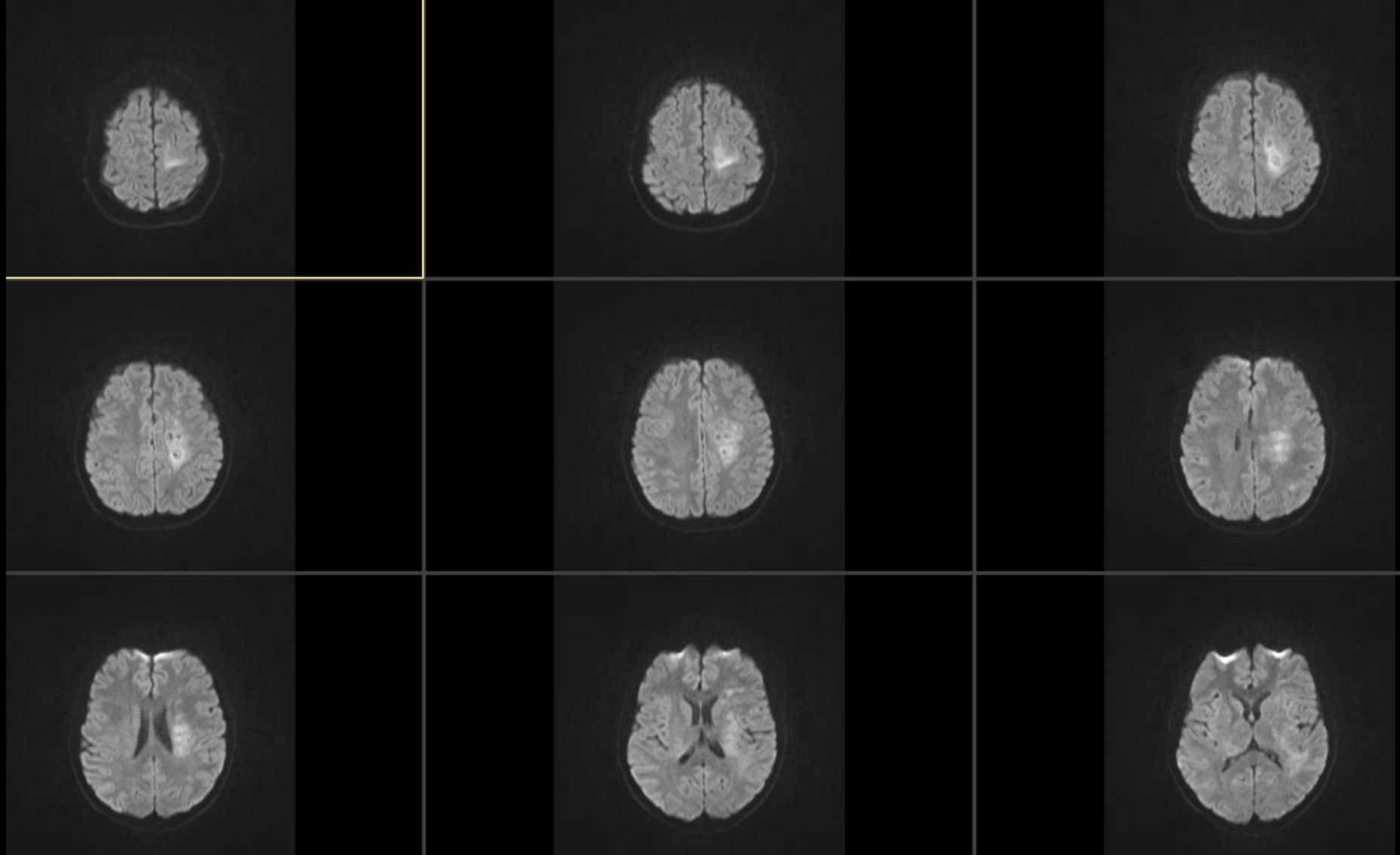
SWI



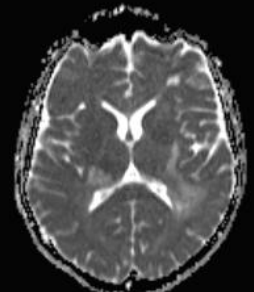
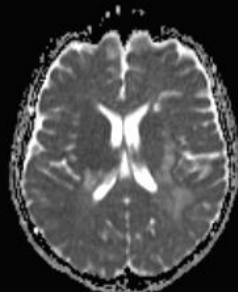
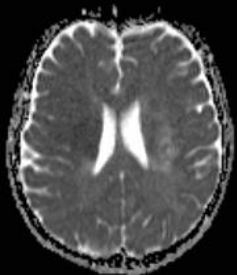
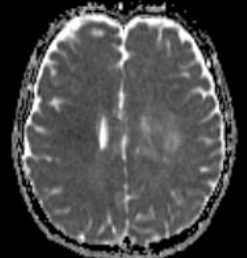
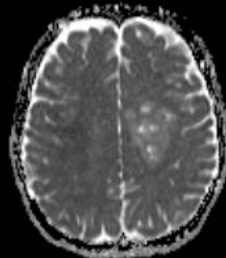
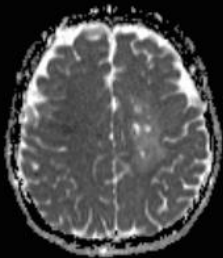
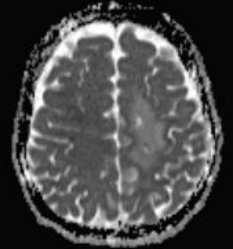
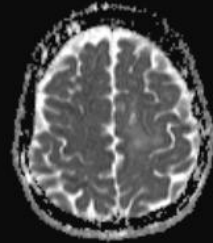
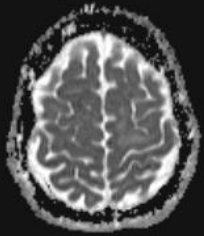
SWI



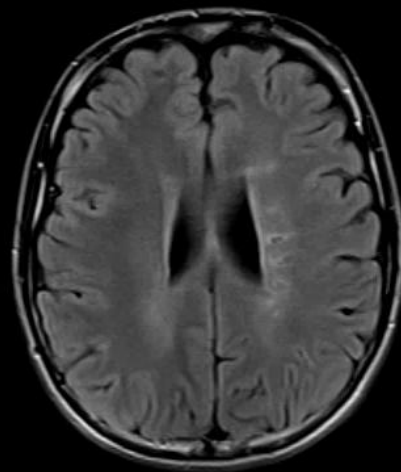
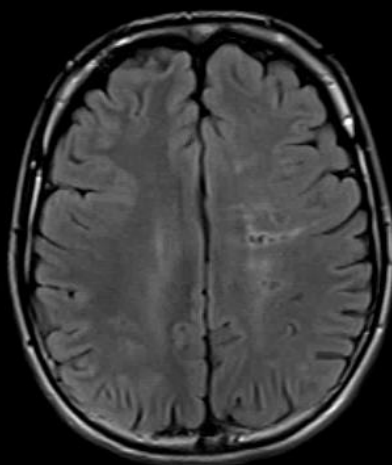
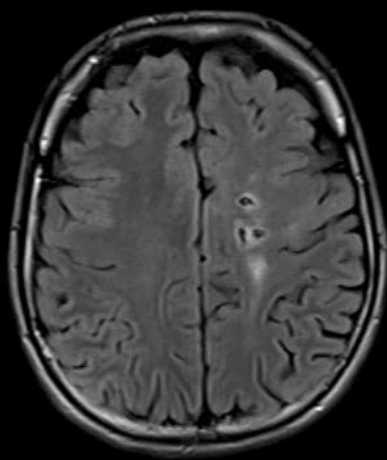
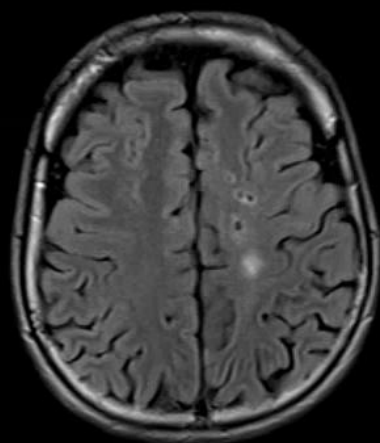
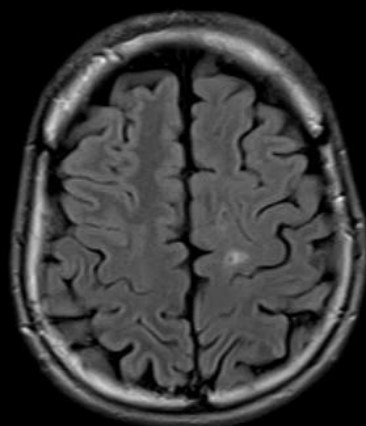
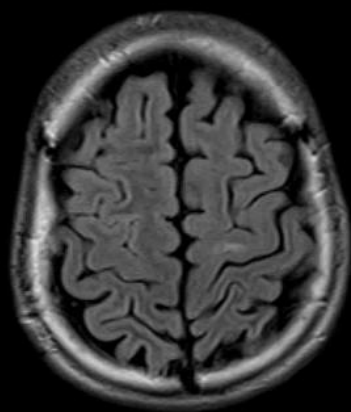
# DWI

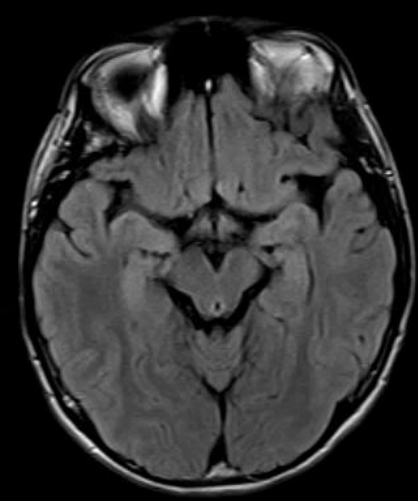
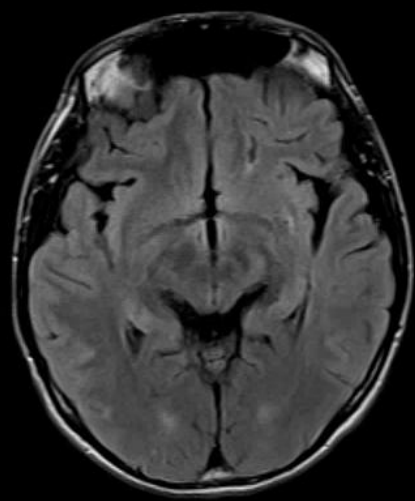
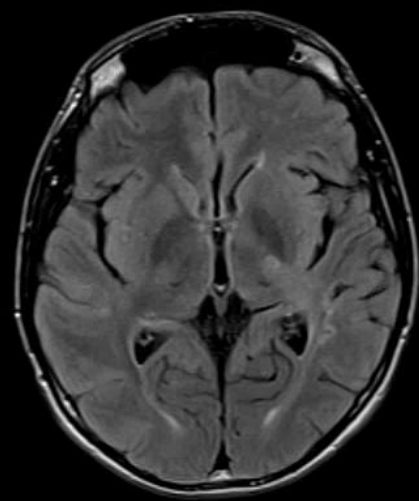
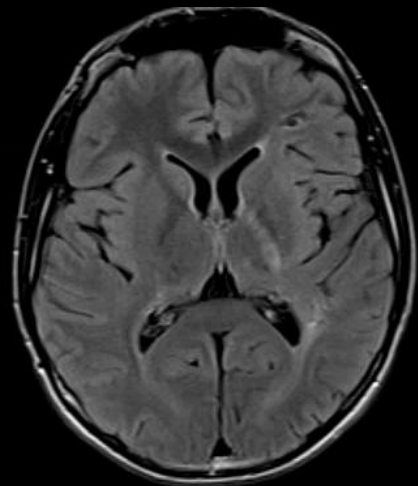
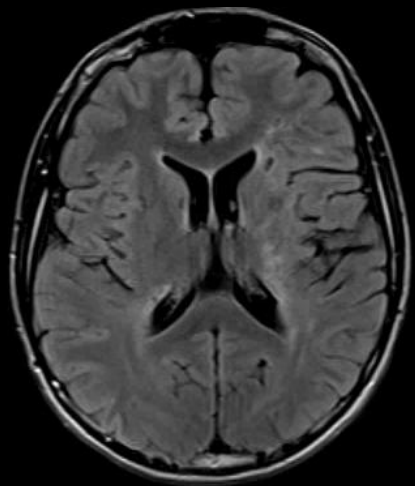
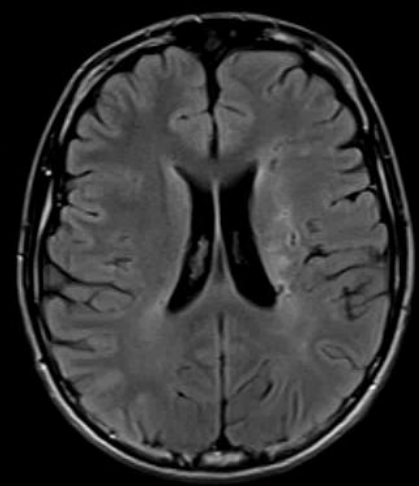


# ADC

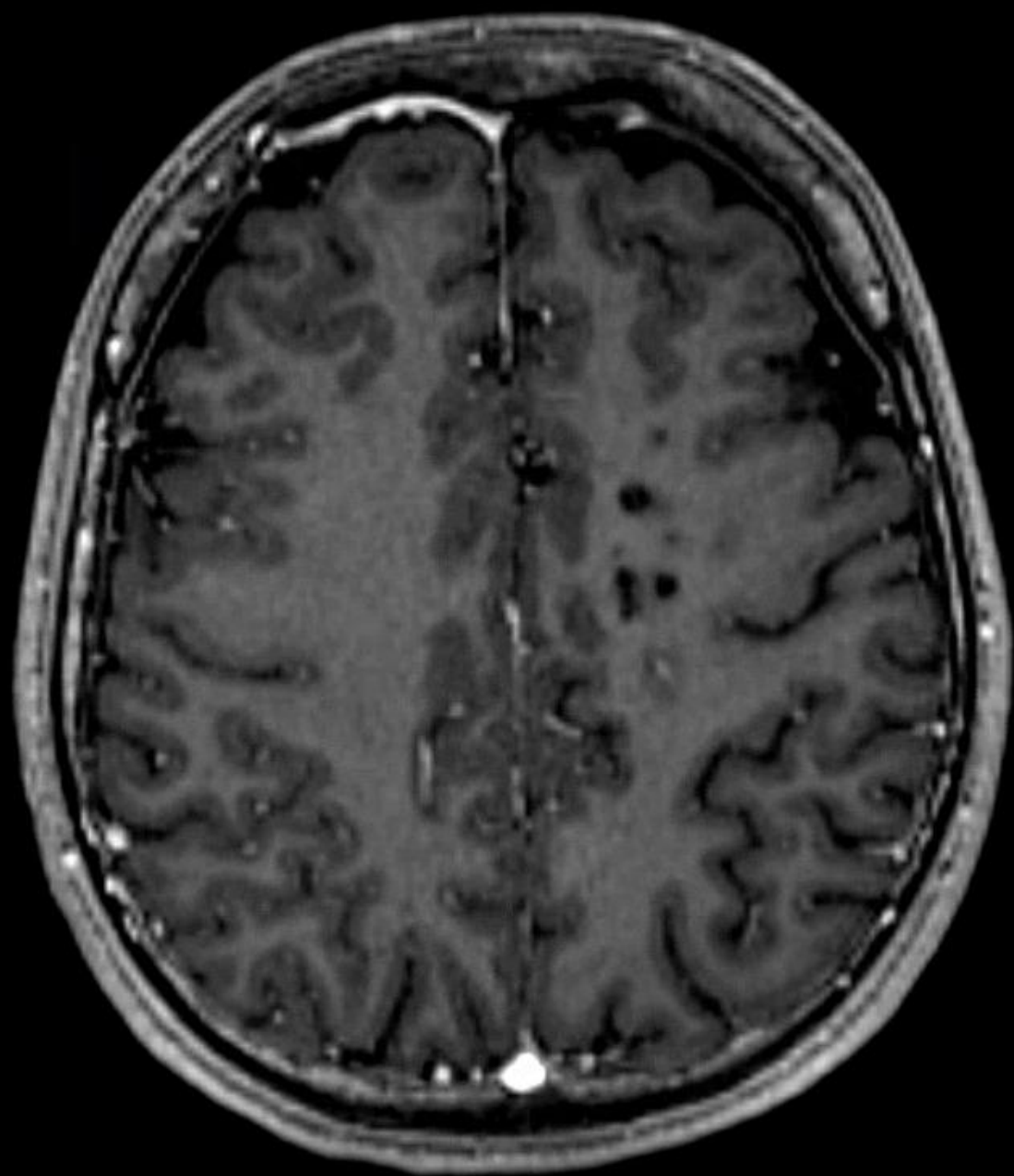


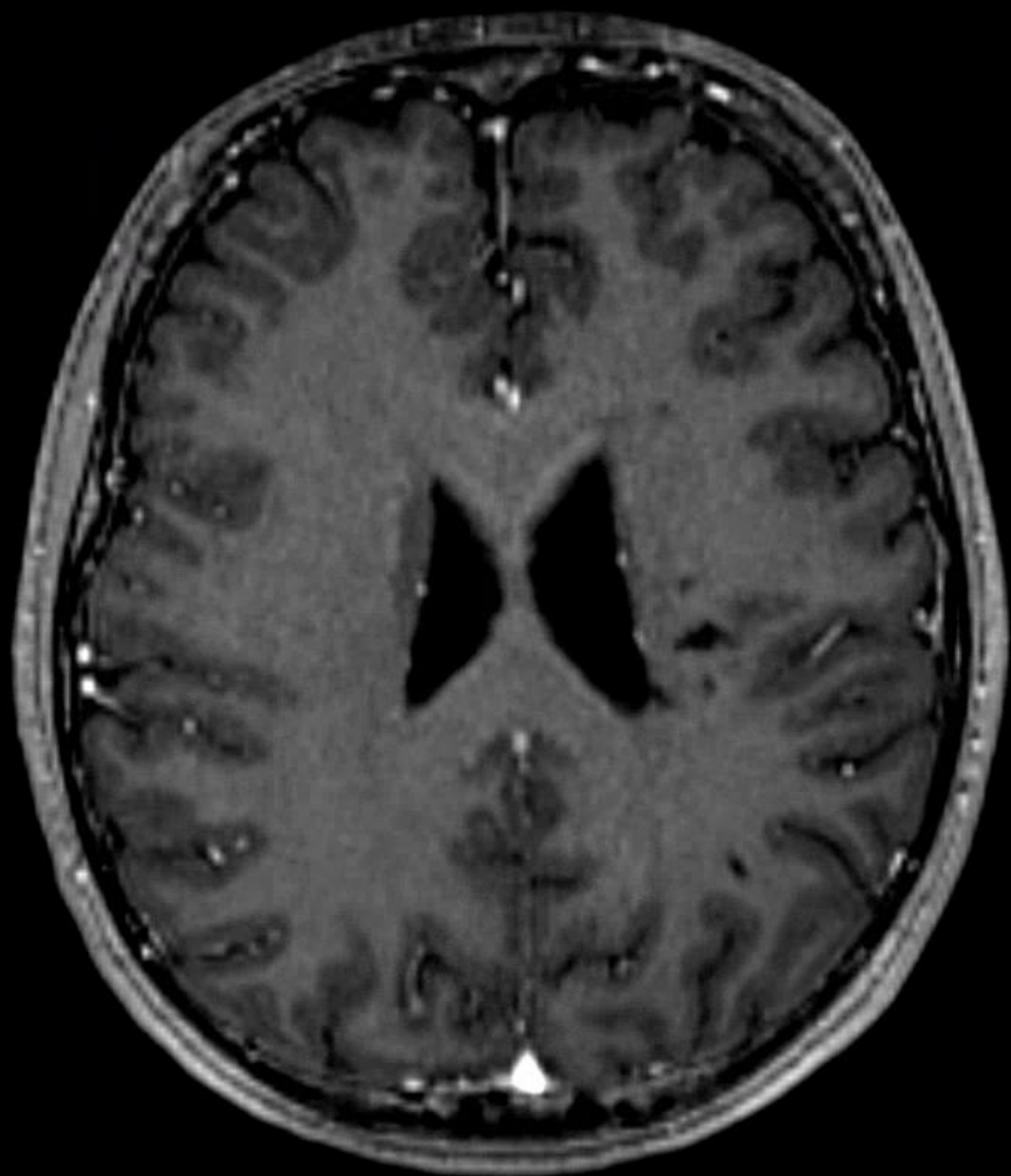
MRI – April 2014

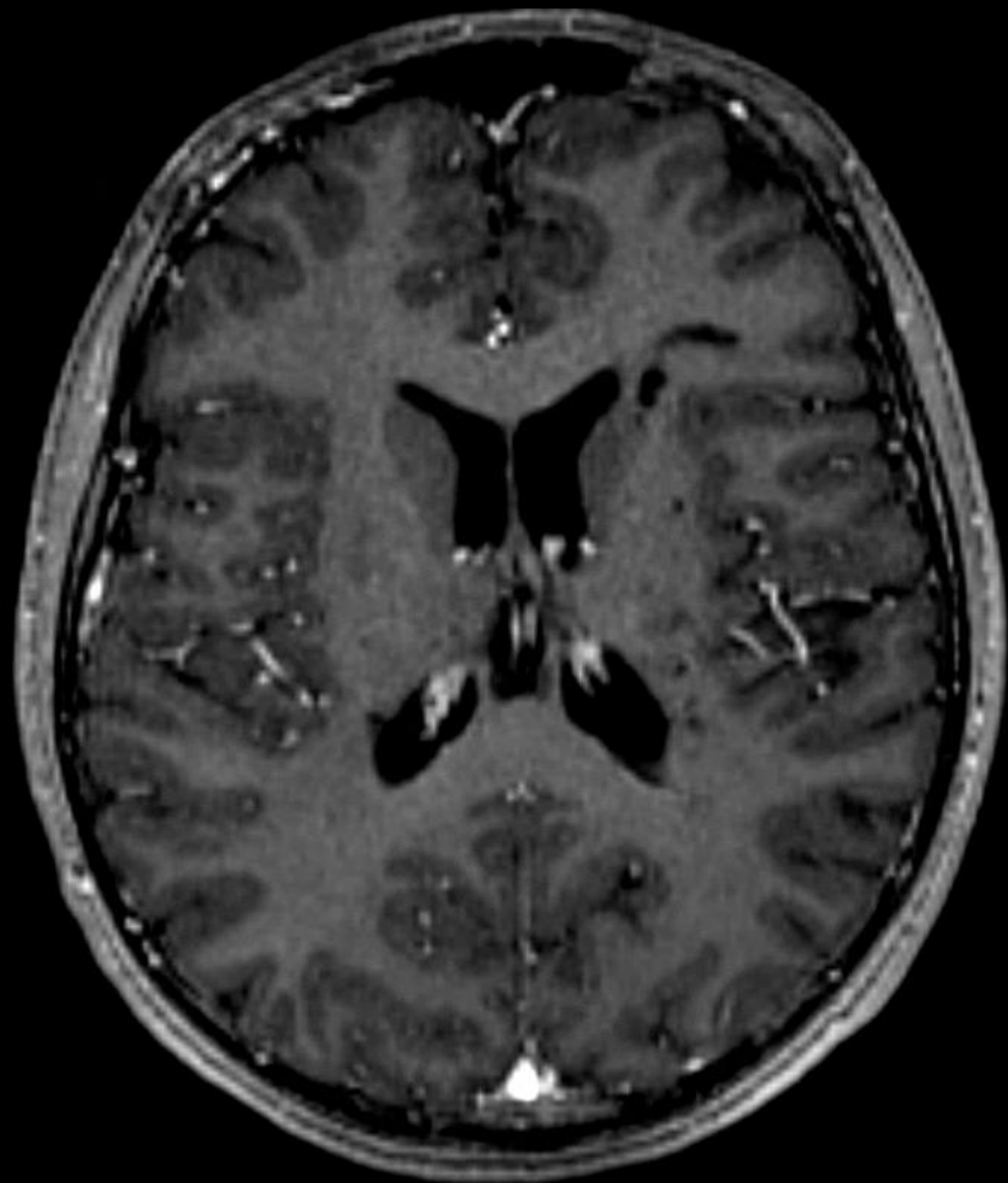


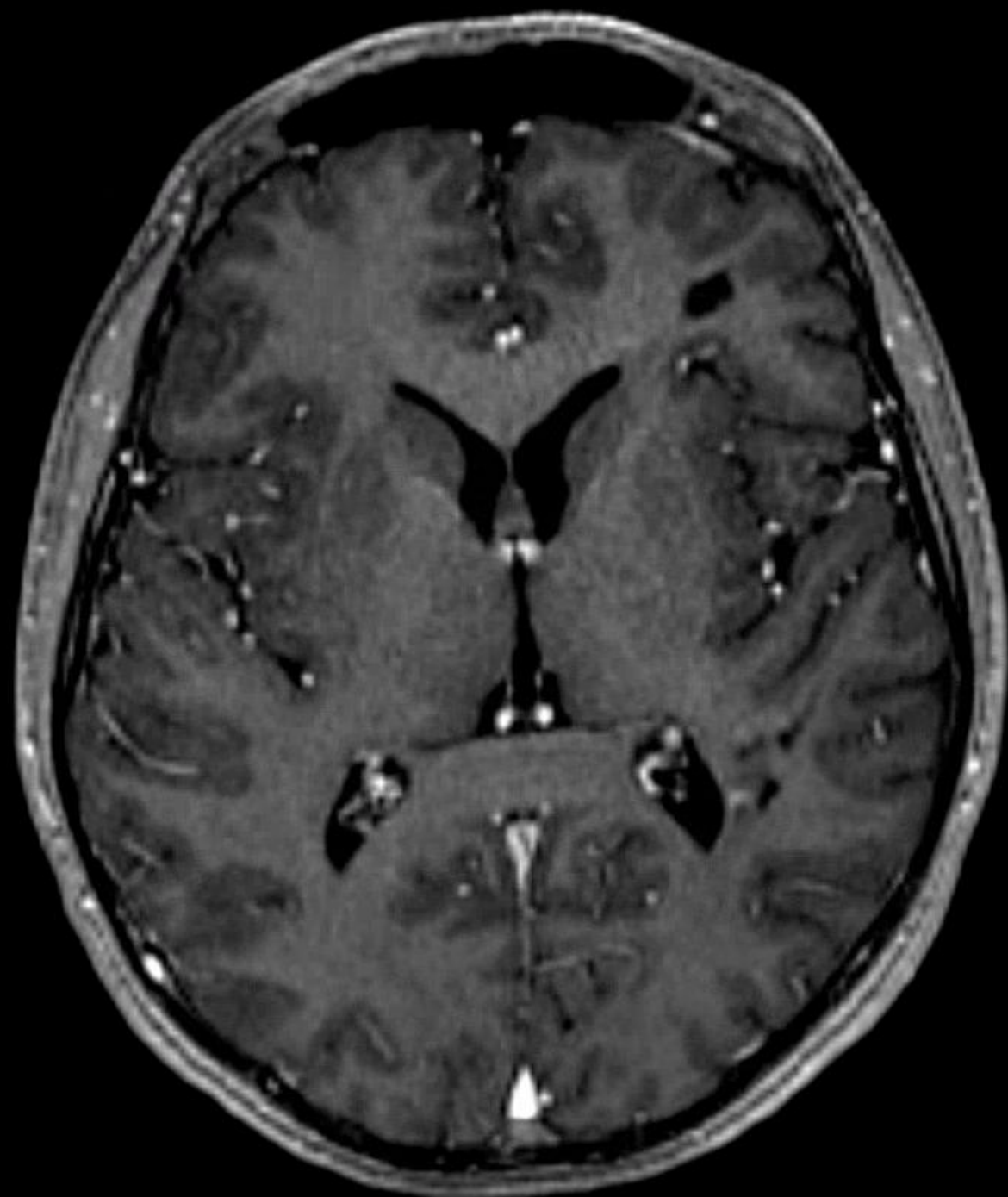




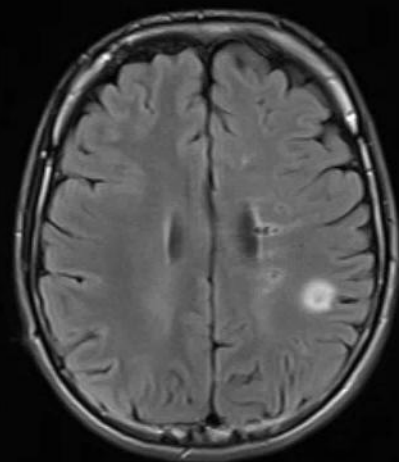
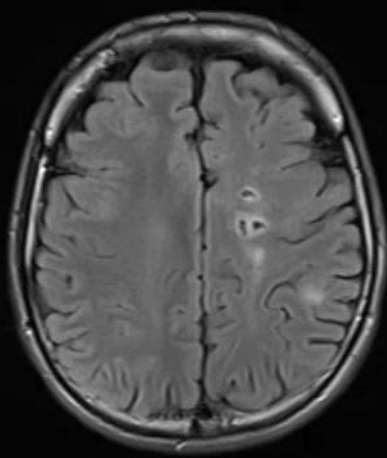
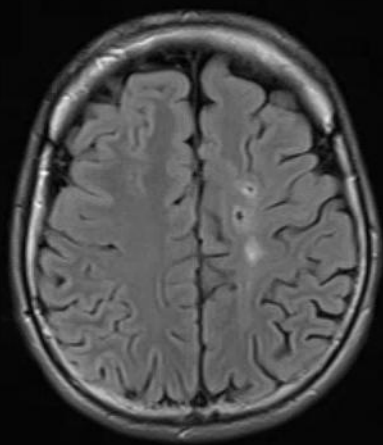
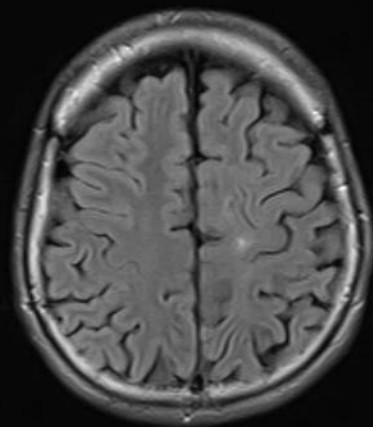
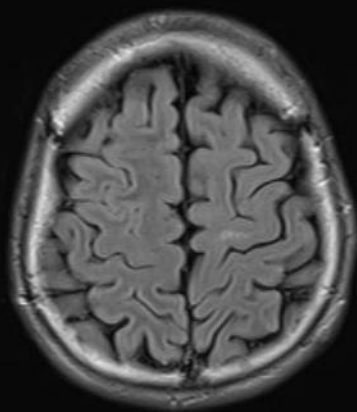
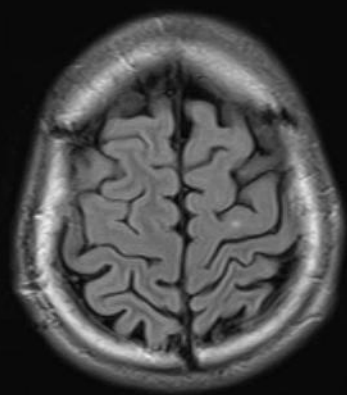


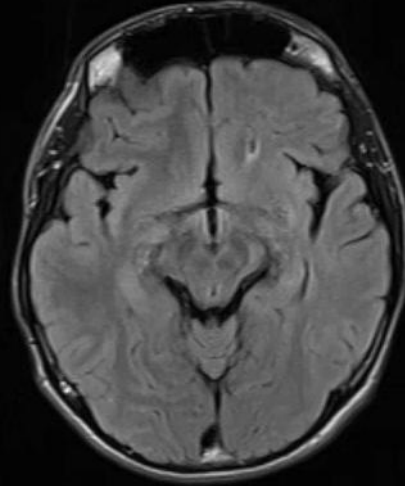
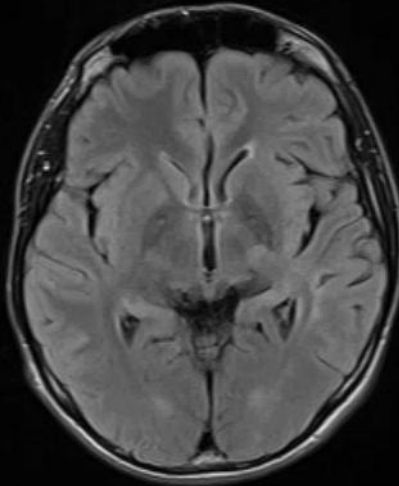
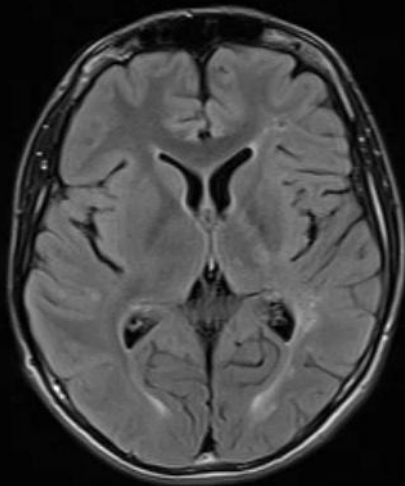
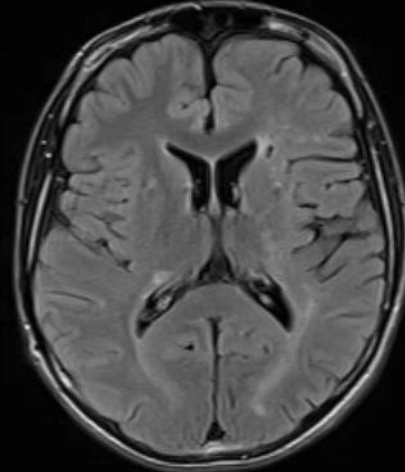
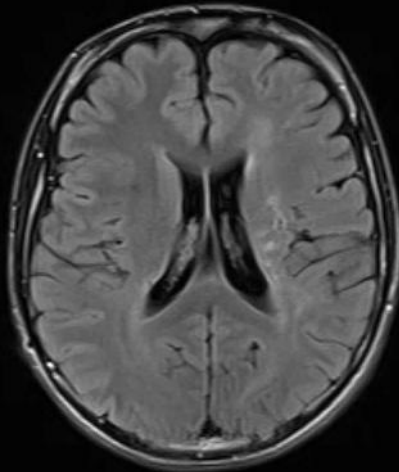
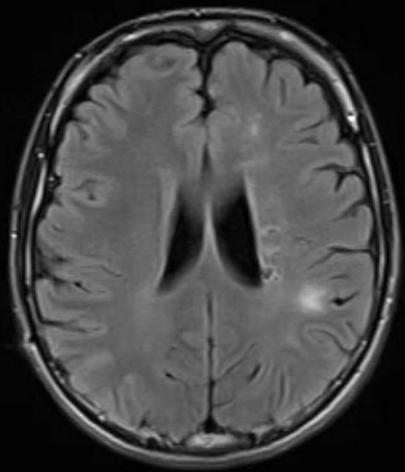


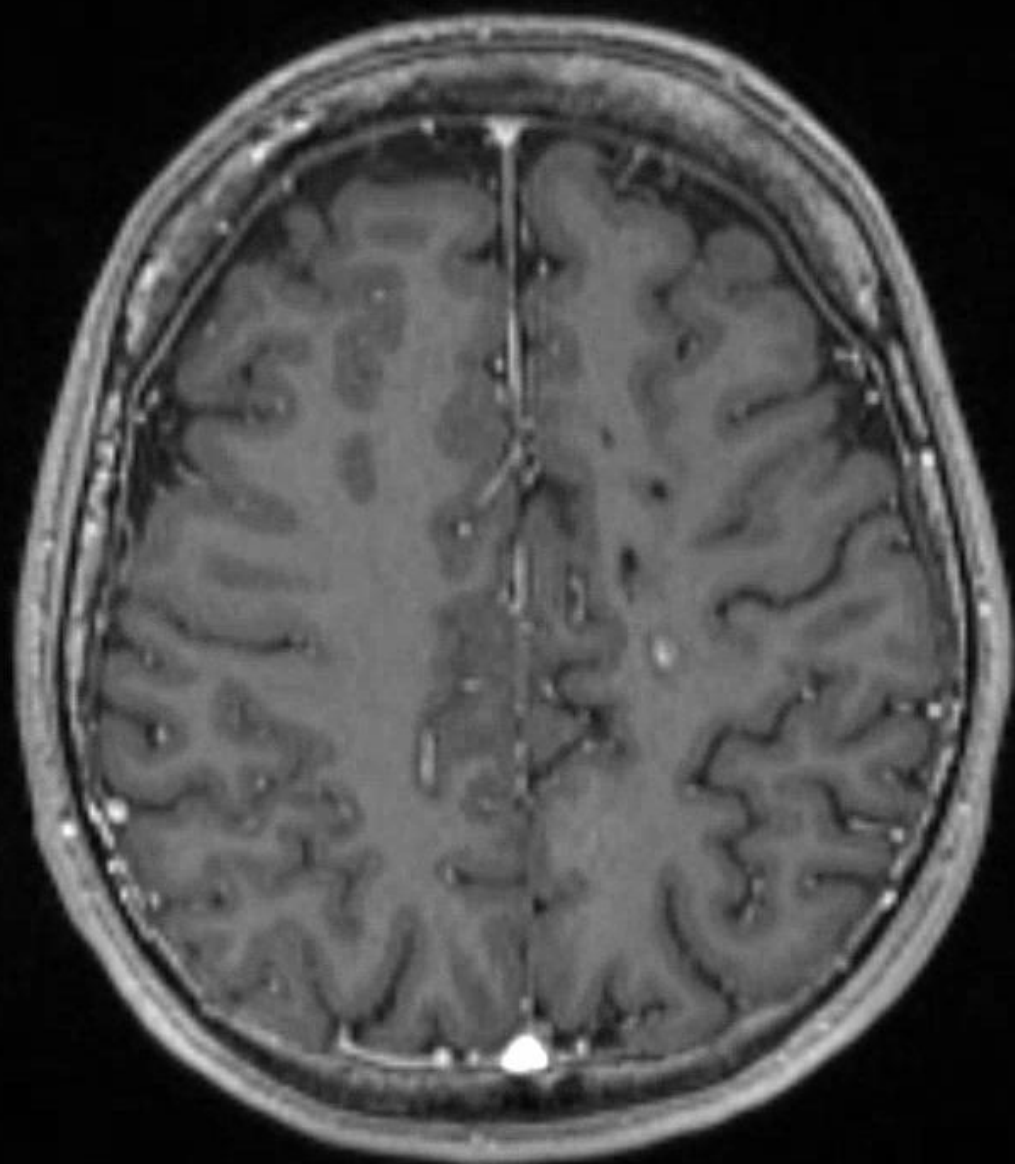




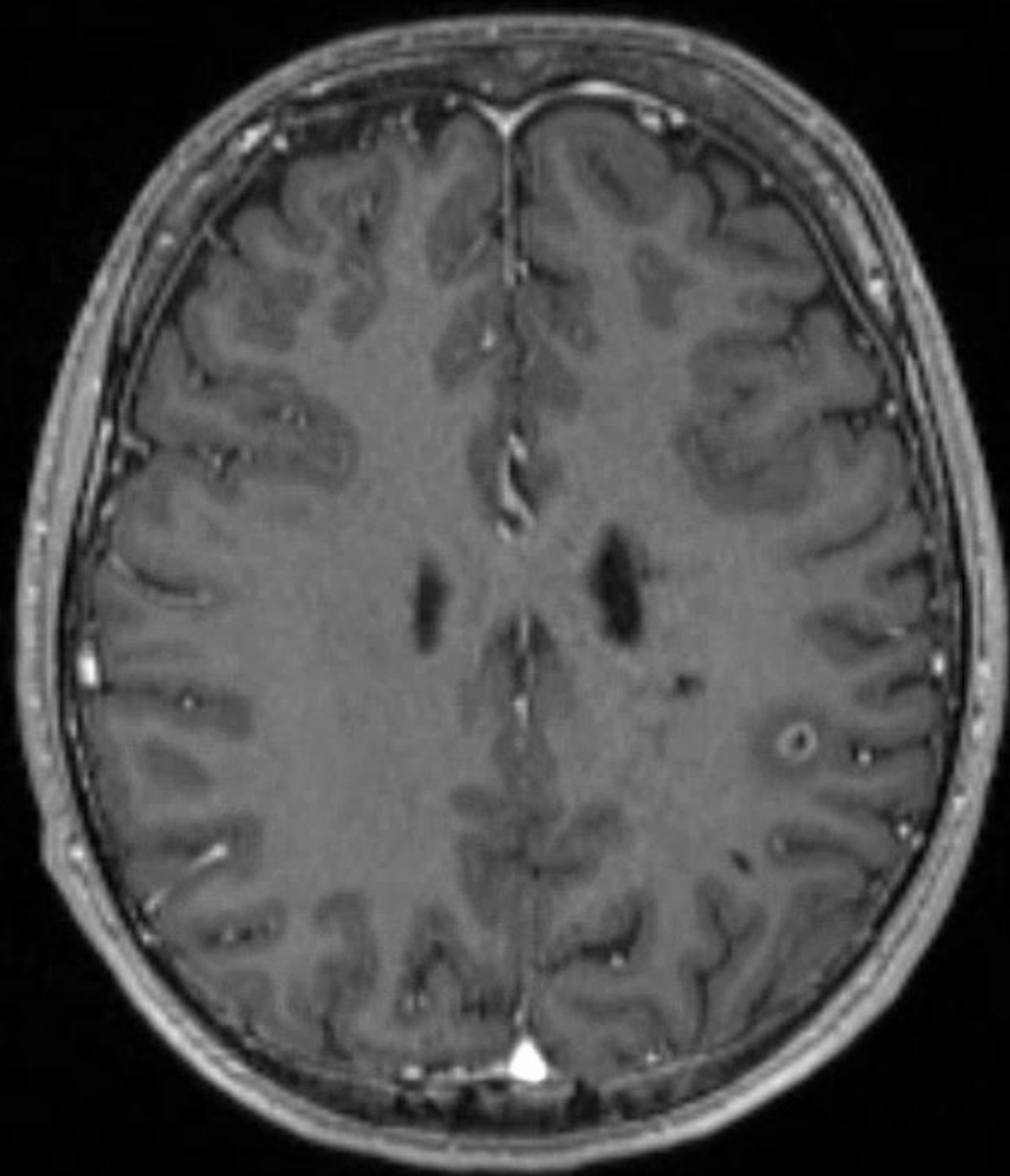
MRI – September 2015

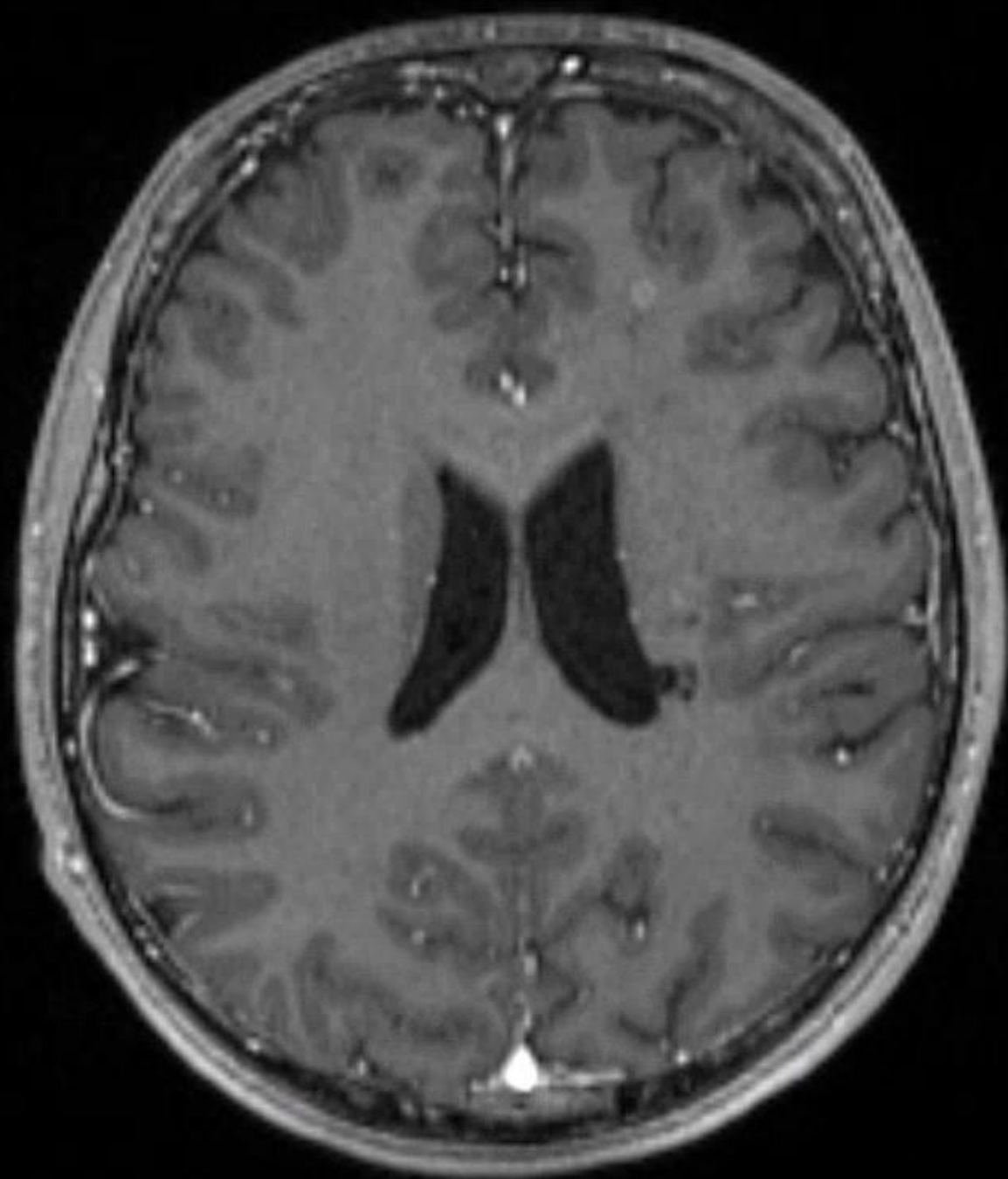


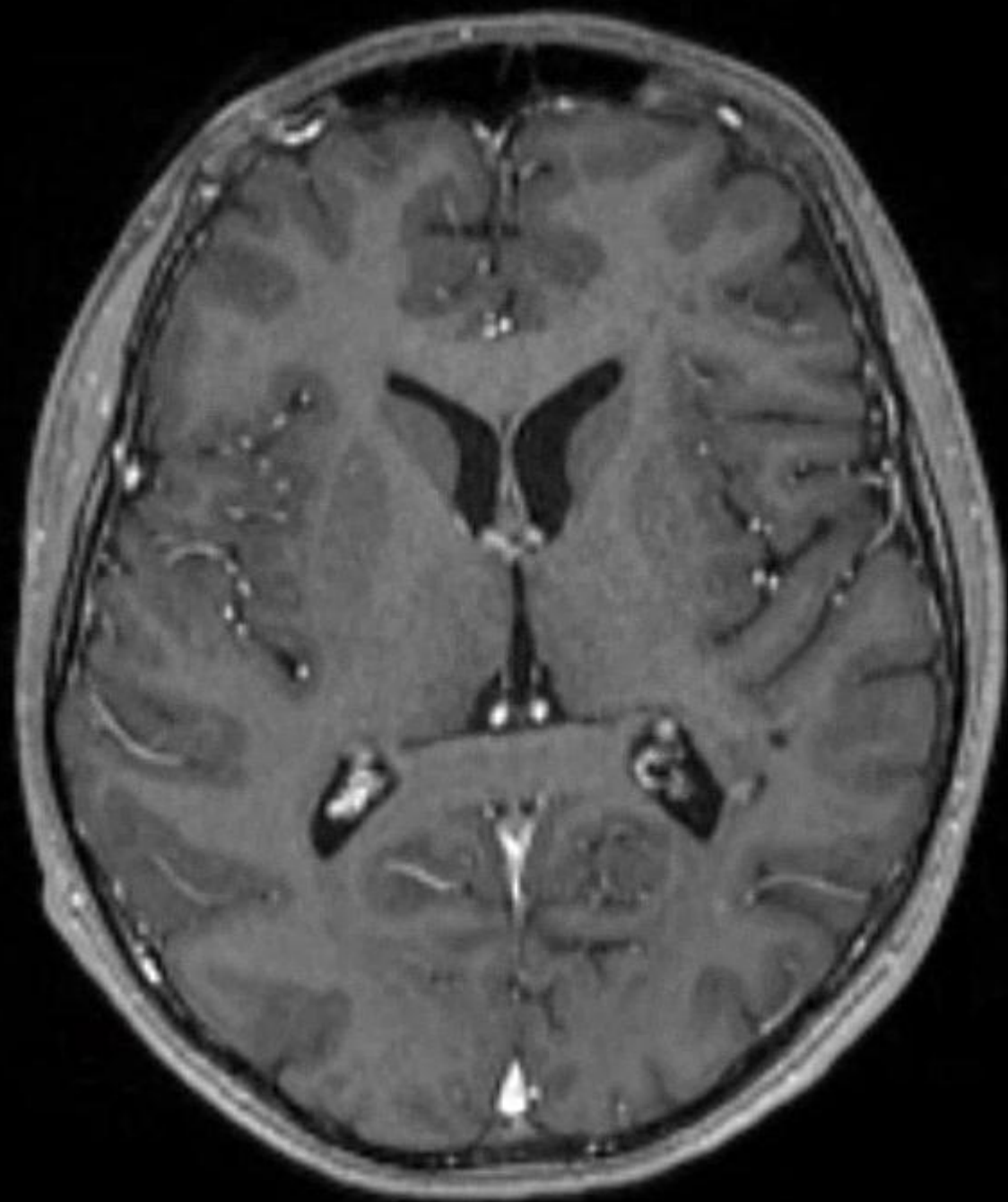












MRI – March 2016

